SCIENCE CHINA
Life Sciences

SPECIAL TOPIC: Brain disease and human cognition
•REVIEW•

https://doi.org/10.1007/s11427-020-1822-4

Magnetic resonance imaging for chronic pain: diagnosis, manipulation, and biomarkers

Yiheng Tu[1,2], Jin Cao[3], Yanzhi Bi[1,2] & Li Hu[1,2,4*]

[1]*CAS Key Laboratory of Mental Health, Institute of Psychology, Beijing 100101, China;*
[2]*Department of Psychology, University of Chinese Academy of Sciences, Beijing 100101, China;*
[3]*Department of Psychiatry, Massachusetts General Hospital and Harvard Medical School, Boston 02129, USA;*
[4]*Department of Pain Management, The State Key Clinical Specialty in Pain Medicine, The Second Affiliated Hospital of Guangzhou Medical University, Guangzhou 510260, China*

Received July 17, 2020; accepted September 15, 2020; published online November 23, 2020

Pain is a multidimensional subjective experience with biological, psychological, and social factors. Whereas acute pain can be a warning signal for the body to avoid excessive injury, long-term and ongoing pain may be developed as chronic pain. There are more than 100 million people in China living with chronic pain, which has raised a huge socioeconomic burden. Studying the mechanisms of pain and developing effective analgesia approaches are important for basic and clinical research. Recently, with the development of brain imaging and data analytical approaches, the neural mechanisms of chronic pain have been widely studied. In the first part of this review, we briefly introduced the magnetic resonance imaging and conventional analytical approaches for brain imaging data. Then, we reviewed brain alterations caused by several chronic pain disorders, including localized and widespread primary pain, primary headaches and orofacial pain, musculoskeletal pain, and neuropathic pain, and present meta-analytical results to show brain regions associated with the pathophysiology of chronic pain. Next, we reviewed brain changes induced by pain interventions, such as pharmacotherapy, neuromodulation, and acupuncture. Lastly, we reviewed emerging studies that combined advanced machine learning and neuroimaging techniques to identify diagnostic, prognostic, and predictive biomarkers in chronic pain patients.

chronic pain, magnetic resonance imaging, biomarkers, machine learning

Citation: Tu, Y., Cao, J., Bi, Y., and Hu, L. (2020). Magnetic resonance imaging for chronic pain: diagnosis, manipulation, and biomarkers. Sci China Life Sci 63, https://doi.org/10.1007/s11427-020-1822-4

Introduction

As a multidimensional and highly complex subjective experience consisting of biological, psychological, and social factors, pain occurs when something hurts, causing an uncomfortable or unpleasant feeling. Acute pain, caused by specific causes, usually comes on suddenly. It goes away when there is no longer an underlying cause for the pain, and a person can go on with life as usual.

In contrast, chronic pain lasts longer than three months, and does not act as a warning signal that acute pain does. It brings tremendous personal and societal burden: chronic pain patients often have increased therapeutic needs and reduced life quality, and society needs to cope with a great number of people with this condition (Davis et al., 2017). Chronic pain is one of the most common reasons for physician visits (Hart et al., 1995) and the leading cause of disability globally (Vos et al., 2012). In China, there are more people living with chronic pain than patients with cancer, heart disease, or diabetes. For example, chronic low back pain (cLBP) is the second leading cause of years lived with disability burden disease in China (Wu et al., 2019). To date,

*Corresponding author (email: huli@psych.ac.cn)

© Science China Press and Springer-Verlag GmbH Germany, part of Springer Nature 2020

treatments for chronic pain are often unsatisfactory (Mao, 2012), which at least partly due to our limited understanding of the underlying pathophysiology of chronic pain.

In the field of pain neuroscience, the emergence of neuroimaging techniques has enabled researchers to non-invasively investigate the role of the central nervous system in the maintenance and development of chronic pain. These technologies, including magnetic resonance imaging (MRI), positron emission tomography (PET), electroencephalogram (EEG), and magnetoencephalography (MEG), have been used to study the abnormal brain functions and structures in patients with chronic pain. Moreover, studies that aimed to develop new pain intervention approaches also applied neuroimaging techniques to associate the changes of brain responses with the changes of chronic pain symptoms, exploring a deeper understanding of the treatment mechanism thus facilitating treatment protocols.

Recent developments in data science, in particular machine learning, have advanced the understanding of chronic pain by exploring large scale and complex clinical and neuroimaging data (Lötsch and Ultsch, 2018). Using data-driven computational approaches, researchers have identified potential neuroimaging-based biomarkers for the diagnosis and prognosis of chronic pain. Furthermore, neural markers that can predict patient's responses to interventions have the great potential to facilitate individualized treatment for chronic pain.

The present review mainly focuses on the studies using MRI technique to study the central nervous system in chronic pain patients. In the first part of this review, we briefly introduce MRI and computational approaches for MRI data. Then, we will review the functional and structural alterations caused by several typical chronic pain disorders, including localized and widespread primary pain, primary headaches and orofacial pain, musculoskeletal pain, and neuropathic pain, and present meta-analytical results to demonstrate the brain regions involved in the chronic pain pathophysiology. In the third part, we will review the brain changes induced by pain interventions, such as pharmacotherapy, neuromodulation, and acupuncture. In the last part, we will review studies that combined advanced machine learning and neuroimaging techniques to identify diagnostic, prognostic, and predictive biomarkers of chronic pain.

MRI and related analytical approaches

Functional MRI

Functional MRI (fMRI) detects brain signal changes that are associated with blood flow, since neuronal activation and cerebral blood flow are highly coupled. The primary form of fMRI, called blood oxygen level dependent (BOLD) imaging, measures small changes of oxygen level in blood. Increases of neuronal activity are associated with increased demand for oxygen, and an increase of oxygen level in blood flow reflects increased neural activity. Hence, tracking changes in blood oxygenation levels can be a proxy of brain activity.

Depending on the context, there are two main experimental settings for fMRI: resting-state fMRI and task fMRI. For resting-state fMRI, a participant is required to keep still and stay awake during the fMRI scan (duration of scan may vary from several minutes to hours). Since brain activity is intrinsic, present even without an explicit task, the BOLD signal in any brain region will have spontaneous fluctuations. Researchers have developed several approaches to quantify the intrinsic brain activity and connectivity. For example, Zang et al. (2007) developed the amplitude of low frequency fluctuations (ALFF) to quantify the regional intensity of spontaneous fluctuations in BOLD signals by calculating the square root of power spectrum within the low-frequency range (0.01–0.08 Hz). To reduce the noise from physiological sources near the ventricles and large blood vessels, an improved version of ALFF, called fractional ALFF (fALFF), was developed to calculate the ratio of the power spectrum of low-frequency range (0.01–0.08 Hz) to that of the entire frequency range (Zou et al., 2008). Since brain regions are not independent but intrinsically organized as networks, resting-state functional connectivity, which measures the interactions between different brain regions, has been extensively studied in healthy and patient populations (Biswal et al., 1995; Rosazza and Minati, 2011). The functional connectivity can be calculated as the correlation (e.g., Pearson's correlation, partial correlation) between the time series of BOLD signals in two regions of interest, indicating the pattern of synchronous activity in these two regions. Recent studies have shown that functional interactions between brain regions are not static during the entire fMRI scan, but can vary considerably in different temporal scales (Damaraju et al., 2014; Hutchison et al., 2013; Kucyi and Davis, 2014; Tu et al., 2019a). The time-varying characteristics may represent spontaneous alterations in the intrinsic networks and may reveal neural mechanisms that cannot be discovered based on the conventional static functional connectivity analyses (Fu et al., 2018a; Fu et al., 2018b; Marusak et al., 2017). Therefore, by adding temporal information, researchers have developed pipelines to analyze dynamic functional connectivity for resting-state fMRI data (Fu et al., 2019; Tu et al., 2019a).

In task fMRI, a participant is instructed to perform an explicit task in the MRI scanner, and his/her brain activity is simultaneously recorded by the MRI. With a clear hypothesis, researchers design a large variety of tasks to investigate the brain functions associated with cognition, motor, or memory. To identify the brain regions and activities involved in a task, a univariate analytical approach called the general

linear model (GLM) has been a core tool (Friston et al., 1994). In brief, the GLM aims to model a dependent variable by a linear combination of several independent variables. Here, the dependent variable can be the observed voxel-wise fMRI time course, and the independent variables can be the expected fMRI time courses for different conditions in an experimental paradigm. The expected fMRI time course is typically obtained by convolving a conditioned course with a standard hemodynamic response function.

Structural MRI and diffusion MRI

Structural MRI examines the anatomy and pathology of the brain. It provides information to qualitatively and quantitatively measure the shape, size, and integrity of gray and white matter structures in the brain. There are many pulse sequences for structural MRI which emphasize different contrasts between brain tissues. For example, the T1-weighted sequence provides a good contrast between gray matter and white matter tissues, and the T2-weighted sequence provides a good contrast between cerebrospinal fluid and brain tissues (Symms et al., 2004). Analytical approaches for structural MRI normally measure the volume, thickness, or surface area of the cerebral cortex, or the shape of gray matter structures.

Diffusion MRI maps the diffusion process of water in the brain. A primary form of diffusion MRI, diffusion tensor imaging (DTI), has been extensively used to map white matter tractography in the brain. There are several common DTI measures, for example, mean diffusivity, fractional anisotropy, radial diffusivity, and axial diffusivity. A complete review of those DTI measures can be found in Alexander et al. (2007).

Functional and structural brain abnormalities in chronic pain

MRI has been widely applied for studying the central nervous system of patients with chronic pain. Using functional and structural MRI, researchers have extensively explored the brain abnormalities in different chronic pain patients and linked those brain abnormalities to the clinical measurements. In the following, we will review the findings for several common chronic pain disorders and provide a meta-analytical result.

Localized chronic primary pain: chronic low back pain

cLBP is the most prevalent chronic pain disorder and has been widely studied using different neuroimaging techniques. Studies using MRI have identified abnormal functional and structural alterations in wide-spread regions, including the primary and secondary somatosensory cortices, paracentral lobule, supplementary motor area (SMA), anterior cingulate cortex (ACC), amygdala, thalamus, and insula (Kregel et al., 2015; Mao and Yang, 2015; Zhang et al., 2019a; Zhang et al., 2019b). In a recent study, performing resting-state fMRI in 90 cLBP patients before and after a pain-exacerbating maneuver, and in 74 healthy controls subjects, Zhang et al. (2019a) studied low-frequency oscillations (indexed by ALFF) in cLBP patients. They found that cLBP patients had increased ALFF in the postcentral gyrus (PoCG), paracentral lobule, SMA, and ACC, while temporal pain exacerbation elevated ALFF in common pain-related areas, such as the insula, amygdala, thalamus, and hippocampus, and decreased ALFF in the default mode network (DMN). This study novelly separated brain patterns associated with neuropathophysiology of cLBP (i.e., comparing cLBP to healthy controls) and temporal intensity alterations of clinical pain (i.e., comparing ALFF before and after pain-exacerbating maneuver), suggesting that brain patterns distinguishing cLBP patients from pain-free controls may be different from those associated with clinical pain intensity.

Moving from studying isolated brain regions, functional connectivity, which measures functional interactions between two brain areas, provides insights at the network level. For example, the default mode network, which plays important roles in higher-order cognitive functions and reflecting individuals' emotional states, has been shown abnormal in cLBP (Apkarian et al., 2004; Baliki et al., 2008; Loggia et al., 2013; Tu et al., 2019b). The salience network, which not only monitors possible changes in sensory input but also coordinates brain activity to facilitate behavioral responses, has been found to be disrupted in cLBP (Borsook et al., 2013; Hemington et al., 2016). The sensorimotor network, which mainly processes sensory information, has been shown to be abnormal in cLBP patients (Kong et al., 2013). The important role of functional connectivity also indicates the prognosis of cLBP. Using the same pain-exacerbating maneuver dataset as that used in Zhang et al. (2019a), Yu et al. (2020a) found that the functional connectivity between the ventral tegmental area (VTA) and ACC was decreased in cLBP patients while increased when back pain intensity was elevated. Different from conventional fMRI functional connectivity analysis, which assumes a constant interaction between different brain regions throughout the entire fMRI scan, Tu et al. (2020a) investigated the transient changes of functional connectivity and examined the thalamocortical dynamics in cLBP patients. They found that distinct thalamocortical networks were associated with cLBP pathophysiology and pain intensity. That is, cLBP patients had abnormal functional connectivity between the ventralateral/posterolateral (VL/VPL) nucleus and PoCG as well as between the dorsal/ventral medial nucleus and insula, while temporal pain in-

tensification altered functional connectivity between the VL/VPL and PoCG and the DMN. In a longitudinal study of 1 year with subacute back pain (SBP) patients, SBP patients were divided into two groups: recovering and persisting patients. Surprisingly, Baliki et al. (2012) showed that initially greater brain connectivity between the nucleus accumbens and prefrontal cortex predicted pain persistence, suggesting that corticostriatal circuit may be an indicator for the transition from acute to chronic pain. Furthermore, by investigating brain white matter properties after onset of acute back pain, the same group found that white-matter fractional anisotropy differences between persisting patients and recovering patients could accurately predict pain persistence over the next year. These results imply that brain structural differences may predispose individuals to pain chronification (Mansour et al., 2013).

Several studies have highlighted the decreased cognitive and emotional regulation in cLBP patients using specific tasks. For example, Mao et al. (2014) used a multisource interference task to evaluate the directed attention in cLBP patients. They found that cLBP patients had reduced task performance as well as significantly reduced activation in the cingulo-fronto-parietal network during attention-demanding trials compared to the healthy participants. In a very recent study, using a monetary incentive delay task, researchers found that cLBP patients had abnormal behavioral and brain responses to reward and punishment. In addition, the decreased brain response in the striatum was related to higher depression and anhedonia scores in cLBP patients (Kim et al., 2020b).

Widespread chronic primary pain: fibromyalgia

Fibromyalgia is characterized by widespread musculoskeletal pain. Studies using MRI have found functional and structural abnormalities in brain regions, including the prefrontal cortex, insula, sensorimotor cortex, and brainstem (Burgmer et al., 2009; Giesecke et al., 2004; Jensen et al., 2013; Jensen et al., 2009; Kuchinad et al., 2007; López-Solà et al., 2017; Martucci et al., 2018; Robinson et al., 2015). Apart from those studies using task-free design, a series of neuroimaging studies have shown abnormal responses to a variety of painful stimuli in fibromyalgia patients (Cagnie et al., 2014; Gracely et al., 2002; Jensen et al., 2013; Pujol et al., 2009). Using pressure-pain stimuli and functional and structural MRI, Jensen et al. (2009) found that fibromyalgia patients showed decreased functional regional coherence, decreased brain volumes and decreased cortical thickness in the rostral ACC. The brain structural changes were more pronounced in patients with longer exposure to fibromyalgia. Although the dysfunction of rostral ACC in fibromyalgia patients has been reported in an early study (Jensen et al., 2009), this combined integration of structure and functional measures highlighted a coherent function-structure brain aberrations and suggested the dysfunctional endogenous pain inhibition as a central pathophysiological mechanism in fibromyalgia.

Studies examining brain connectivity have revealed abnormal networks in fibromyalgia patients (Flodin et al., 2014; Ichesco et al., 2016; Kim et al., 2015; Napadow et al., 2010; Napadow et al., 2012). During rest, fibromyalgia patients showed decreased functional connectivity between the premotor cortices and thalamus, between the primary sensorimotor cortex and right insula, and between the prefrontal and supramarginal cortices (Flodin et al., 2014; Napadow et al., 2010). A longitudinal study has shown that the reduction of intrinsic DMN connectivity to the insula was coupled to the reduction in pain intensity. When receiving nociceptive stimulation, fibromyalgia patients had increased functional connectivity between pain-related brain regions (e.g., the thalamus and insula) and the DMN (Flodin et al., 2014; Ichesco et al., 2016). In a study with 42 fibromyalgia patients and 63 pain-free adults, Kim et al. (2015) found abnormal cerebellar connectivity to temporal, medial prefrontal, and right inferior parietal lobes. In addition, they explored white matter connectivity using probabilistic white matter tractography and showed that the number of white matter fibers in the frontal and cerebellar networks was associated with the pain sensitivity and clinical pain interference. These converging results indicate that altered gray and white matter morphometry in the frontal and cerebellar regions may jointly contribute to pain-related dysfunctions in fibromyalgia patients.

Fibromyalgia patients are also suffered from reward dysfunction. Using pain-related reward/punishment paradigm, Loggia et al. (2014) found that fibromyalgia patients exhibited reduced activation during both pain anticipation and relief anticipation within the brain regions associated with sensory, cognitive, and affective functions. In particular, activity in the ventral tegmental area, the origin of the dopaminergic reward system, was abnormal during anticipation of pain relief and punishment. In another study using a monetary incentive delay task and fMRI to measure neural correlates of reward anticipation and female fibromyalgia patients, the authors found altered prefrontal and striatal brain activity for the monetary anticipation and outcome (Martucci et al., 2018). Together, these results implicate altered mesocortical and mesolimbic dopaminergic pathways for reward processing in fibromyalgia patients.

Chronic primary headaches and chronic orofacial pain

Primary headaches are the most common and disabling neurological disorders worldwide. Neuroimaging studies have transformed our understanding of headache from a vascular to neurovascular, and most recently, to a central

nervous system disorder. Using MRI, researchers have identified functional and structural brain abnormalities in cortical and subcortical regions in migraine and cluster headache patients (Aurora et al., 1999; Coppola et al., 2016; Hodkinson et al., 2016; Messina et al., 2018; Mulleners et al., 2001; Schwedt, 2013; Schwedt et al., 2015; von Deneen et al., 2019).

Almost 132 million people in China are living with migraine (Stovner et al., 2018), and the prevalence is around 10% of the whole Chinese population. Migraine includes prodrome, aura (migraine without aura patients do not have this stage), headache, postdrome, and interictal stages. Studies have shown functional abnormalities in the visual cortex, hypothalamus, spinal trigeminal nucleus, and pons in the prodrome phase (Schulte and May, 2016), while the visual cortex was also found abnormal in the aura (Arngrim et al., 2017) and postdrome (Schulte and May, 2016). During aura, the visual cortex was found abnormal. About 30% of patients have aura symptoms, which may be due to the cortical spreading depression, a wave of cortical depolarization that is followed by neuronal suppression (Goadsby et al., 2017). Using fMRI, Arngrim et al. (2017) studied different patterns of brain responses during induced visual aura symptoms. They found a reduced BOLD response in the visual cortex when experiencing negative visual symptoms (e.g., scotoma) and an increased BOLD response in the visual cortex when experiencing positive symptoms (e.g., flickering).

During headache, i.e., ictal phase, widespread brain areas were disrupted, including the cerebellum and periaqueductal gray (Mehnert and May, 2019), hypothalamus (Schulte et al., 2017; Schulte and May, 2016), pons (Hougaard et al., 2017), spinal trigeminal nucleus and visual cortex (Schulte and May, 2016), middle frontal, somatosensory and temporooccipital cortex (Hougaard et al., 2017), and thalamus (Amin et al., 2018). One recent study included a patient with migraine without aura and scanned MRI for 30 consecutive days to identify the migraine "generator" in the hypothalamus (Schulte and May, 2016). The study showed dysregulated functional connectivity between the hypothalamus and the spinal trigeminal nuclei and dorsal pons during the prodrome and ictal phase. The authors suggested that the hypothalamus may be the generator of migraine attacks. Another study from the same research group found that an elevated activity in the anterior hypothalamus responded to pain only in chronic migraine, but increased activity in the posterior hypothalamus was found in both chronic and episodic migraine patients during ictal phase (Schulte et al., 2017), suggesting that the anterior hypothalamus may play a role in migraine chronification. Since most migraine patients experience multisensory dysfunction, the thalamus as the central relay station was found abnormal during spontaneous attacks of migraine (Amin et al., 2018). At the network level, some studies reported abnormal functional connectivity during the ictal phase in networks that are associated with attentional, cognitive, and emotional modulations of pain (Chong et al., 2019; Coppola et al., 2018).

The interictal phase is one of the most extensively studied stages for migraine. Studies have found functional and structural abnormalities in regions associated with pain and multisensory integration, such as the thalamus (Tu et al., 2019a), somatosensory cortex and visual cortex (Tu et al., 2020b), periaqueductal gray (Chen et al., 2017), and hippocampus (Chong et al., 2017; Liu et al., 2018). Network-based analyses have shown alterations in the default mode network (Hubbard et al., 2014; Tessitore et al., 2013; Xue et al., 2012), sensorimotor network (Zhang et al., 2017), and cognitive network (Androulakis et al., 2017). Using the dynamic functional connectivity analysis, Tu et al. (2019a) investigated the transient changes of functional connectivity and examined the thalamocortical dynamics in interictal migraine without aura patients. They found that abnormal posterior thalamus (pulvinar nucleus) dynamic connectivity with the visual cortex and the precuneus were associated with the headache frequency of migraine, depicting an extended understanding of abnormal thalamocortical networks and dysrhythmia in migraine (Tu et al., 2019a). Interestingly, two recent studies using network-based approaches have identified the decreased functional connectivity between the visual cortex (the V3 and V3A) and other cortical areas (Burke et al., 2020; Tu et al., 2020b), which extended previous findings demonstrating reduced connectivity between the visual cortex and cortical areas in salience network using a seed-based approach (Niddam et al., 2016). In particular, only migraine without aura patients were included in Tu et al. (2020b), implicating that the significance of the visual cortex in relation to the pathophysiology of migraine was independent of visual auras. Migraine is twice more prevalent in females than in males. By collecting structural MRI data from interictal migraineurs and healthy controls with both genders, Maleki et al. found that, as compared with male migraineurs and healthy controls of both sexes, female migraineurs showed thicker posterior insula and precuneus cortices. They further used heat stimulation to investigate functional brain activity and connectivity in these two regions, and showed differences of functional connectivity between male and female migraineurs (Maleki et al., 2012). These results suggest that sex-specific patterns may be associated with migraine. Moreover, suffering from migraine could be stressful and modulate brain functions not only in the pain system in ways that could be maladaptive (Borsook et al., 2012).

Early neuroimaging studies have suggested a key role of the hypothalamic region in cluster headache (May et al., 1998). Specific activation during the pain phase was found in the posterior inferior hypothalamus for patients with "in-bout" cluster headache (May et al., 1998), and a following

study using structural MRI revealed concurrent increase of the gray matter volume in the posterior inferior hypothalamus (May et al., 1999). Another study found an increased hypothalamic volume in the anterior hypothalamus when patients with cluster headache were compared to migraineurs and healthy controls (Arkink et al., 2017). These studies have suggested that the anterior and posterior hypothalamus may be distinctly involved in the pathophysiology of clustered headache: whereas the anterior hypothalamus could be associated with the generation of the circadian rhythm of cluster headache attacks, the posterior hypothalamus might contribute to the restlessness that is commonly experienced by cluster headache patients during the attack (Hoffmann and May, 2018).

One of the most common chronic orofacial pain is the temporomandibular disorders. Studies have observed functional abnormalities in the primary somatosensory cortex (Abrahamsen et al., 2010), attentional/emotional, motor and default mode networks (Weissman-Fogel et al., 2011); structural abnormalities in the frontal polar, primary somatosensory cortex, and ventrolateral prefrontal cortex (Moayedi et al., 2011); and aberrant white matter fractional anisotropy near the primary somatosensory cortex (Moayedi et al., 2012).

Chronic musculoskeletal pain: osteoarthritis

Among all arthritis conditions, knee osteoarthritis is the most prevalent and disabling degenerative joint disorder. Chronic pain is a hallmark of knee osteoarthritis, and the spontaneous pain of knee osteoarthritis is distinguishable from the acute pain. Using fMRI, Parks et al. found that knee osteoarthritis patients had disrupted spontaneous brain activities in prefrontal-limbic regions, which also had been observed abnormal in other chronic pain. In contrast, patients had similar brain activations to mechanical pain stimuli as compared to healthy controls (Parks et al., 2011). A later study using electrical stimulation to induce pain in healthy controls and knee osteoarthritis patients found that the functional connectivity between the dorsolateral prefrontal cortex and the pain matrix (a cerebral signature for pain perception (Legrain et al., 2011)) was disrupted in knee osteoarthritis patients (Hiramatsu et al., 2014). Brain structure changes have also been found in knee osteoarthritis patients. A very recent study investigated the brain gray matter abnormalities in patients with knee osteoarthritis and hip osteoarthritis using the conventional voxel-based morphometry analysis (Barroso et al., 2020), and the authors found a lower volume of anterior cingulate gray matter only in hip osteoarthritis patients. When they flipped the brains to examine the hemisphere contralateral to osteoarthritis pain, the volume of primary motor cortex gray matter was lower in the knee and hip pain. However, the reduction of gray matter volume in osteoarthritis patients was not significantly associated with their clinical symptoms (Barroso et al., 2020) and pain sensitivity (Alshuft et al., 2016).

Chronic neuropathic pain: trigeminal pain

Neuropathic pain is a main category of chronic pain associated with neurological lesions in the peripheral or central nervous system. Trigeminal neuropathic pains have been widely studied using neuroimaging techniques. Studies have found disrupted functional brain activities in the anterior cingulate cortex, prefrontal cortex, and primary somatosensory cortex (Becerra et al., 2006; Henderson et al., 2013; Moisset and Bouhassira, 2007); abnormal gray matter changes in the thalamus, anterior cingulate cortex, primary somatosensory cortex, and insula (DeSouza et al., 2013; Gustin et al., 2011; Obermann et al., 2013); and aberrant white matter fractional anisotropy near the primary somatosensory cortex in trigeminal pain patients (DeSouza et al., 2014; Gustin et al., 2012).

Meta-analytical results for chronic pain

To identify chronic pain-associated brain regions, Neurosynth (http://neurosynth.org/) was used as a metadata reference for neuroimaging literature (Yarkoni et al., 2011). Under the search string “chronic pain”, 92 studies were identified. We further screened the studies to exclude (i) studies using experimental pain on healthy subjects; (ii) studies performed on nonhuman primates. Then we separated studies using fMRI and sMRI since the functional and structural abnormalities may not converge. The final list for the meta-analysis includes 43 studies using fMRI and 20 studies using sMRI. A complete list can be found in Tables S1 and S2 in Supporting Information. We then run the standard coordinate-based meta-analysis with activation likelihood estimation (ALE) (Eickhoff et al., 2009). In brief, ALE models the reported coordinates from each study in a probabilistic fashion that the reported foci are treated as the center of an uncertainty function (with Gaussian probability distribution). For all activation foci in each subject, ALE provides probabilities for each voxel and returns an individual activation map. Then ALE estimates the convergence of those individual activation maps by finding the union of the probabilities and provides voxel-wise scores representing the convergence of activation at each location. Last, ALE defines the P-value by comparing the proportion of values under a null distribution reflecting a random spatial association between studies. In our analysis, the significance threshold was set to $P<0.001$ at the voxel level, and a cluster-level family-wise error corrected significance of $P<0.05$ based on 10,000 Monte-Carlo simulations.

Functional abnormalities were mainly found in the insula,

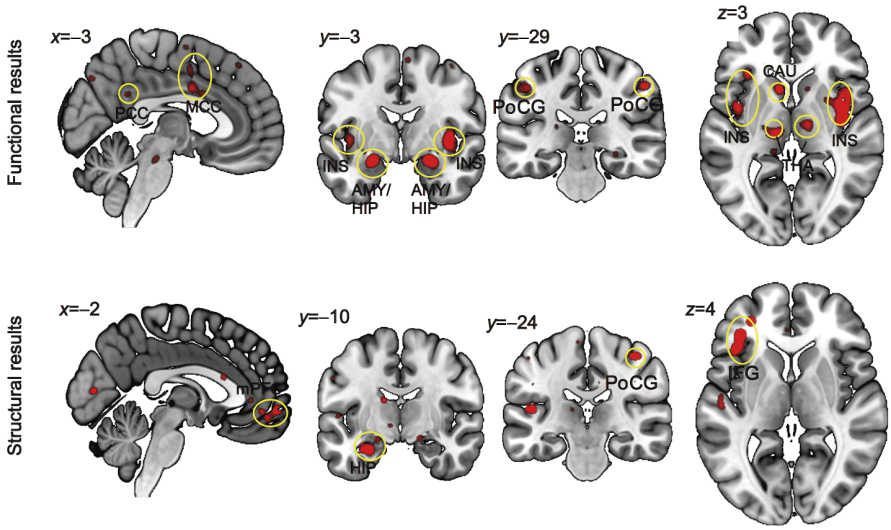

Figure 1 Meta-analytical results. Brain regions associated with chronic pain were identified and extracted from 43 fMRI studies and 20 sMRI studies. PCC, posterior cingulate cortex; INS, insula; AMY, amygdala; HIP, hippocampus; THA, thalamus; PoCG, postcentral gyrus; MCC, Middle cingulate cortex; mPFC, medial prefrontal cortex; CAU, caudate; IFG, inferior frontal gyrus.

PoCG, thalamus, middle cingulate cortex, amygdala, hippocampus, and posterior cingulate cortex (Figure 1). In addition, structural abnormalities were mainly found in the medial prefrontal cortex, hippocampus, postcentral gyrus, and inferior frontal gyrus. The coordinates for the identified regions can be found in Tables 1 and 2.

Functional and structural brain changes due to the treatment of chronic pain

Pharmacotherapy is the most common treatments for chronic pain, and a large number of pharmaceuticals have been suggested as treatment options for chronic pain. The opioid analgesics, considered to be the most powerful analgesic agent for the treatment of chronic pain, have led to consequences of misuse, overdose, and addiction (i.e., opioid epidemic), and the treatment effect for reducing pain was limited when comparing to placebo (Baron et al., 2010). In recent years, researchers are increasingly assessing the potential benefits of neuromodulatory interventions and psychological interventions in treating various pain conditions (Jensen et al., 2014). Using neuroimaging analytical approaches, studies have explored the underlying mechanisms of different treatment approaches in chronic pain patients. In the following sections, we will review recent findings of functional and structural brain changes due to three different classes of treatments of chronic pain, including pharmacotherapy, neuromodulation, and acupuncture.

Pharmacotherapy

The subanesthetic ketamine is often recommended for treating a variety of chronic pain conditions, especially for neuropathic pain (Niesters et al., 2014). Rogers et al. (2004) used fMRI to investigate the analgesic effects of ketamine and found that ketamine significantly reduced thermal pain and brain activity in the thalamus and insula. In another placebo-controlled fMRI study investigating the effects of ketamine on intrinsic functional connectivity (Niesters et al., 2012), the authors reported that ketamine increased the connectivity in the visual cortex and cerebellum, and decreased connectivity in the somatosensory and auditory cortices. These studies explored the ketamine's mechanism in the central nervous system with respect to analgesia for experimental pain. To link the changes in pain symptoms and the changes in the brain under chronic pain conditions, researchers recruited chronic pain patients and scanned their brains before any intervention. Then those patients were randomized into different intervention groups and received corresponding treatments in several weeks or months. Another neuroimaging scan was applied at the end of treatment sessions. In a pilot study, Becerra and colleagues reported the fMRI brain changes in a patient with complex regional pain syndrome who received ketamine treatment. They scanned the patient twice: one during pain state and another after ketamine treatment in the pain-free state (Becerra et al., 2009), and found that the patient had different brain activations in the cortical and subcortical regions when receiving pain stimuli. Moreover, they found that the patient's resting-state network was modulated towards the patterns of healthy volunteers. A recent study by Rogachov et al. (2019) further tested the hypothesis that the effect of pain-relieving due to ketamine is the result of a reversal of brain abnormalities. They showed that ketamine decreased regional low-frequency brain oscillations in the posterior cingulate cortex,

Table 1 Coordinates of chronic pain-associated brain regions identified from meta-analysis of fMRI studies[a)]

Cluster ID	Brain regions	Peak coordinates			Peak *T* value	Cluster size (voxels)
		x	*y*	*z*		
1	Brain stem/midbrain	0	−24	−18	3.26	45
2	R PHG/HIP/THA/AMY	24	0	−16	5.56	404
3	L PHG/HIP/AMY/STG	−22	−4	−16	4.83	168
4	R INS/PUTA/IFG/STG/Oper	40	4	2	4.94	691
5	L INS/Oper/PreCG/STG	−42	2	0	4.17	260
6	L IFG/INS	−34	26	2	3.84	81
7	L CAU	−10	14	2	4.02	57
8	L THA/PUTA	−12	−20	4	3.90	166
9	L THA/HIP/PHG	−14	−34	6	3.37	40
10	R PoCG/Oper	52	−16	18	3.29	33
11	R ACC/MFG	12	36	16	3.90	56
12	L IFG/MFG/PreCG	−54	4	38	3.10	41
13	R ACC/MCC/	2	2	34	3.55	47
14	L MCC	−4	−22	36	3.86	38
15	PCu/IPL	0	−74	42	3.71	80
16	L MCC/PCC/PCu	−4	−44	42	3.59	32
17	L IPL/PoCG	−46	−32	46	3.67	140
18	R IPL/PoCG/SMG	52	−28	48	3.61	57

a) L, left; R, right; PHG, parahippocampal gyrus; HIP, hippocampus; THA, thalamus; AMY, amygdala; STG, superior temporal gyrus; INS, insula; IFG, inferior frontal gyrus; MFG, middle frontal gyrus; ACC, anterior cingulate cortex; MCC, middle cingulate cortex; PCC, posterior cingulate cortex; PUTA, putamen; Oper, operculum; CAU, caudate; PreCG, precentral gyrus; PoCG, postcentral gyrus; PCu, precuneus; IPL, inferior parietal lobule; SMG, supramarginal gyrus.

Table 2 Coordinates of chronic pain-associated brain regions identified from the meta-analysis of sMRI studies[a)]

Cluster ID	Brain regions	Peak coordinates			Peak *T* value	Cluster size (voxels)
		x	*y*	*z*		
1	L PHG/HIP/AMY	−30	−10	−22	3.81	125
2	L IFG/SFG/INS	−26	16	−20	3.66	47
3	L HIP/PHG/AMY	−20	−14	−14	3.26	32
4	L MFG/SFG/ACC	−2	58	−6	3.43	66
5	R MTG/STG	52	−32	0	3.44	31
6	L IFG/MFG/INS	−38	34	4	4.09	143
7	L MFG	−30	46	6	3.84	44
8	L STG/PoCG/SMG/IPL/INS/Oper	−48	−24	12	3.91	117
9	L CUN/SOG	−4	−84	8	3.37	30
10	R SFG/MFG	8	66	16	3.56	35
11	L ACC	−4	18	20	3.31	42
12	L SOG/CUN/PCu/SPL	−16	−64	26	3.58	38
13	R SFG/PreCG/PoCG/SPL	50	−18	38	3.90	67
14	R ParaCG/PoCG/PCu/SPL	18	−40	58	3.54	32
15	R PreCG/PoCG/SFG	40	−24	56	3.70	65

a) L, left; R, right; PHG, parahippocampal gyrus; HIP, hippocampus; AMY, amygdala; STG, superior temporal gyrus; INS, insula; IFG, inferior frontal gyrus; MFG, middle frontal gyrus; SFG, superior frontal gyrus; ACC, anterior cingulate cortex; STG, superior temporal gyrus; MTG, middle temporal gyrus; Oper, operculum; PreCG, precentral gyrus; PoCG, postcentral gyrus; ParaCG, paracentral gyrus; PCu, precuneus; CUN, cuneus; IPL, inferior parietal lobule; SPL, superior parietal lobule; SMG, supramarginal gyrus; SOG, superior occipital gyrus.

and the treatment response was associated with the decrease of functional connectivity between the posterior cingulate cortex and sensorimotor and salience networks.

Duloxetine is a medicine used to relieve chronic pain and

improve mood. Studies have suggested that the analgesic effect of duloxetine may be associated with the modulation of the endogenous pain inhibitory pathway (Jones et al., 2005). In several clinical studies, duloxetine is effective in treating patients with diabetic neuropathic pain (Goldstein et al., 2005), fibromyalgia (Arnold et al., 2004), knee osteoarthritis (Chappell et al., 2011; Chappell et al., 2009), and cLBP (Skljarevski et al., 2009; Skljarevski et al., 2010). Using fMRI, a study found that duloxetine could significantly reduce brain responses to painful stimulation, in regions of right prefrontal cortex, pregenual anterior cingulate cortex, and pons (López-Solà et al., 2010). Although duloxetine has been shown effective for treating chronic pain, few neuroimaging studies have investigated the central mechanisms in the patient population.

Neuromodulation

With the increasing understanding of the pathophysiology of chronic pain, non-invasive brain stimulation techniques that can target pain-related brain regions have been considered as effective treatments for chronic pain. In particular, cortical stimulation procedures, such as repetitive transcranial magnetic stimulation (rTMS) and transcranial direct current stimulation (tDCS), have the potential to modulate pain (Jensen et al., 2014). rTMS is delivered by stimulating cortical tissue via a magnetic coil placed near the scalp above the target brain region. A magnetic field is produced to penetrate the skull when a current is passed through the coil. High-frequency stimulation (≥5 Hz) could lower thresholds of neuronal firing and thereby increase brain excitability, while low-frequency stimulation (≤1 Hz) could increase the firing threshold and thereby inhibit excitability. tDCS is delivered by administrating a weak current (1–2 mA) to the scalp via pre-placed electrodes, usually for tens of min per session. The current provided via the positive electrode (anodal) could lower the firing threshold of the neurons that lie in the cortex under the electrode, thereby increase neuronal excitability. Whereas negative electrode (cathodal) could increase the firing threshold of the neurons below the electrode and inhibit neuronal excitability. Previous studies using rTMS and tDCS normally targeted the primary motor cortex contralateral to the painful region, since brain activity in the primary motor cortex may inhibit the processing of nociceptive inputs by sending modulatory signals directly to the thalamus and consequently reduce pain (O'Connell et al., 2010; Plow et al., 2012). Preliminary clinical trials have shown effective pain reduction that could persist days to weeks after treatment (Fenton et al., 2009; Fregni et al., 2007; Fregni et al., 2006; Lefaucheur et al., 2006; Mhalla et al., 2011; Mori et al., 2010; Tzabazis et al., 2013). Using fMRI and rTMS/tDCS on the primary motor cortex, studies have reported widespread effects on cortical (e.g., cingulate and frontal cortices), subcortical (e.g., thalamus, striatum), and brainstem (e.g., periaqueductal grey) structures (Marlow et al., 2013). These findings suggest that the effects of non-invasive brain stimulation may be more general and widespread, other than focusing on the targeted brain area. Moreover, the modulatory effects can be in the same (Stagg et al., 2009) or opposite (Antal et al., 2011) direction to that predicted from the polarity of stimulation over the target region.

Although promising, several reviews have pointed out the great variability in pain reduction among studies using non-invasive brain stimulation techniques (Marlow et al., 2013; O'Connell et al., 2010; Plow et al., 2012). Many factors may contribute to this heterogeneity. First, the effects may differ across different types of pain. For example, studies reported that rTMS was more effective in reducing central neuropathic pain than peripheral neuropathic pain (Leung et al., 2009), and it was also more effective in chronic neuropathic pain than in non-neuropathic pain (O'Connell et al., 2010) using the same stimulation protocol. Second, the influences of stimulation parameters (including the intensity, frequency, duration, and the number of sessions) on the analgesic effect are still not well understood. Combining neuroimaging with non-invasive brain stimulation, especially with simultaneously recorded neuroimaging data, will greatly deepen our understandings of these basic questions and facilitate the development of effective stimulation protocols for relieving chronic pain (Esmaeilpour et al., 2020; Venkatakrishnan and Sandrini, 2012).

Acupuncture

As one of the oldest healing arts in the world, acupuncture is a therapeutic intervention by inserting fine, solid metallic needles into or through the skin at specific sites. Acupuncture has been widely used as a form of alternative or complementary treatment for chronic pain. Extensive clinical trials have explored the effectiveness of acupuncture for reducing pain in different chronic pain disorders. In 2012, A meta-analysis conducted on data from 29 randomized controlled trials with a total of 17,922 patients showed that acupuncture was more effective than both sham and no-acupuncture controls (Vickers et al., 2012). Patients receiving acupuncture had a greater reduction of pain than sham controls for back and neck pain, osteoarthritis, and chronic headache. Following this study, an updated meta-analysis conducted on 39 randomized trials with a total of 20,827 patients also confirmed that acupuncture was superior to sham control as well as no acupuncture control (Vickers et al., 2018). They also found that the analgesic effects of acupuncture persist over time, with an approximately 15% decrease only over a year.

Acupuncture is originated from China. As a part of tradi-

tional Chinese medicine, it is based on an ancient physiological system, but not based on Western scientific empiricism. According to the ancient system, health is considered as the result of harmony among bodily functions and between body and nature (Berman et al., 2010). Nevertheless, its unclear neural mechanism has significantly hindered the development and application of acupuncture treatment in western countries. During the past two decades, researchers have been using fMRI to characterize the effects of acupuncture in the central nervous system and visualize its modulation in the brain. Early in 2000, a study used fMRI to investigate the effects of acupuncture in healthy participants and found that the needle manipulation of acupuncture on hand produced significantly decreased fMRI responses in the limbic and subcortical regions, including the nucleus accumbens, amygdala, hippocampus, parahippocampus, hypothalamus, ventral tegmental area, anterior cingulate cortex, caudate, putamen, temporal pole, and insula (Hui et al., 2000). This study provided a foundation for future studies on neural mechanisms of acupuncture. In 2005, researchers further compared the central effects of electroacupuncture at 2 Hz and 100 Hz with traditional Chinese manual acupuncture (Napadow et al., 2005). They found that in addition to the limbic and subcortical brain regions modulated by manual acupuncture, electroacupuncture produced signal increases in the anterior middle cingulate cortex. Later studies have investigated the neural mechanisms of acupuncture analgesia. Kong et al. (2009) found that acupuncture can reduce brain responses to noxious stimuli in typical regions involved in pain processing, including the thalamus, insula, and periaqueductal grey. Using network-based analysis, Dhond et al. (2008) found that real but not sham acupuncture produced increased default mode network connectivity with pain (i.e., the anterior cingulate cortex and periaqueductal grey), affective (amygdala), and memory (hippocampus) related brain regions. These studies collectively provided solid evidence of acupuncture analgesia that may target both sensory and affective pain perception and be implicated in endogenous opioidergic modulation.

Benefited from findings of acupuncture analgesia in experimental pain studies, researchers have also explored the analgesic effects of acupuncture on chronic pain patients. Napadow et al. (2007) found that acupuncture can increase brain activations in the hypothalamus and decrease brain activations in the amygdala in patients with carpal tunnel syndrome as compared to healthy controls. This is the first report showing that as compared to healthy controls, chronic pain patients respond differently to acupuncture via a coordinated limbic network. Several studies have explored the modulatory effects of acupuncture on knee osteoarthritis patients (Chen et al., 2014; Egorova et al., 2015). They found that real acupuncture decreased the functional connectivity between the periaqueductal grey and hippocampus, and the decrease of functional connectivity was associated with the pain reduction in knee pain patients. In contrast, sham acupuncture decreased functional connectivity between the periaqueductal grey and medial frontal cortex, but patients did not show any pain reduction. In addition to functional changes in the brain, longitudinal brain structural analysis showed that knee pain patients who received sham acupuncture (as compared to patients in the real acupuncture group) had significantly reduced the cortical thickness at the left posterior medial prefrontal cortex, suggesting that acupuncture may prevent cortical thinning to achieve therapeutic effects in knee pain patients. The therapeutic effects of acupuncture on migraine patients have been extensively studied (Li et al., 2015; Li et al., 2016; Li et al., 2017a; Li et al., 2017b; Zhao et al., 2017). It has been found that for migraine patients, acupuncture treatment could reverse the abnormal functional connectivity between the periaqueductal grey and rostral anterior cingulate cortex, which is a key pathway in the descending pain modulatory system. The changes in functional connectivity were significantly associated with headache intensity improvement (Li et al., 2016). Similar brain evidence has also been found in cLBP patients (Kim et al., 2020a; Yu et al., 2020a; Yu et al., 2020b). Real acupuncture could increase the functional connectivity between the periaqueductal grey and amygdala, and the increased functional connectivity was associated with decreased pain scores in cLBP patients (Yu et al., 2020b). Kim et al. (2020a) found that acupuncture could reduce the gray matter volume in the primary somatosensory cortex and increase white matter fractional anisotropy of the primary somatosensory cortex. The changes in brain measures were associated with improvements in tactile acuity in chronic back pain patients.

fMRI has facilitated the innovation of acupuncture for treating chronic pain. Conventional acupuncture therapies have been limited by cost and scheduling difficulties. Cao et al. (2018) combined acupuncture with guided imagery to develop a novel intervention, called video-guided acupuncture imagery treatment, which was achieved by watching a video of acupuncture that was administered previously on the participant's own body at baseline while imaging the brain being concurrently applied. They found that both real acupuncture and the imagined acupuncture could significantly increase pain threshold (i.e., less sensitive to pain) as compared to sham treatments. Using fMRI, they examined the different analgesic mechanisms of acupuncture and imagined acupuncture, which may target the insula and rostral anterior cingulate cortex, respectively. More recently, they applied the novel imagined acupuncture to cLBP patients and found that it was also effective in reducing chronic pain (Cao et al., 2020). Since patients could self-administer the imagined acu-

puncture after an exposure of a real acupuncture treatment session, it may be particularly useful for elderly or disabled patients who have limited access to acupuncture treatment.

Machine learning and neuroimaging for identifying pain biomarkers

With the development of data science techniques, the strategy of analyzing large scale neuroimaging data has been transformed from univariate to multivariate ways (Hu and Iannetti, 2016; Su et al., 2019; Woo et al., 2017). In particular, machine learning is a set of algorithms that can detect patterns in neuroimaging data automatically and then apply the identified patterns to observe and extract information from the data to derive new knowledge to predict or classify future data (Lötsch and Ultsch, 2018). Accumulating studies have demonstrated that machine learning is able to extract useful information from high-dimensional and noisy neuroimaging data, thereby identifying neural "biomarkers" for behaviors and diseases (Huang et al., 2013; Wager et al., 2013; Woo et al., 2017). To study chronic pain, researchers have combined neuroimaging with machine learning to develop biomarkers including (i) diagnostic biomarker which is a measure to indicate a certain condition or chronic pain disorder; (ii) prognostic biomarker which has potentials to predict the transition from acute to chronic pain; and (iii) predictive biomarker which could be used to predict the response to a treatment, either beneficial or adverse effects (van der Miesen et al., 2019). In this session, we will focus on recent studies of combining fMRI with machine learning classifiers or regressors to identify diagnostic, prognostic, and predictive biomarkers.

Diagnostic biomarker

A recent study has reviewed pain research involving machine learning and found an increasing number of publications over time (Lötsch and Ultsch, 2018). Most studies combined MRI with machine learning to solve a classification problem, i.e., separate patients with chronic pain and healthy participants. Given the width and depth of machine learning, we will not explain the algorithms in this review. In general, a machine learning classifier takes the values of various features of the brain (e.g., fMRI brain connectivity, sMRI brain volume) as independent variables or predictors from a subject, and predicts the class that the subject belongs to. Figure 2 shows a framework of using MRI and machine learning to develop a diagnostic biomarker for chronic pain. To build a reliable MRI-based biomarker, we first need to recruit many participants, including both healthy participants and chronic pain patients, and collect their MRI and clinical data. After preprocessing MRI data, we need to determine feature types using prior knowledge on brain organization, and then extract corresponding features, for example, functional connectivity and gray matter volume. The machine learning classifier requires training, that is, the classifier learns the association between brain features and their corresponding class labels (i.e., chronic pain patients or healthy subjects). The trained classifier can be applied to the novel or unseen data (i.e., a new cohort of subjects) to determine whether the features contain the discriminative information between classes of new subjects. If the trained classifier contained the information about the relationships between features and labels, it could be able to predict the classes of samples in the unseen data.

The most widely applied machine learning classifier is the support vector machine (SVM), which constructs a hyper-

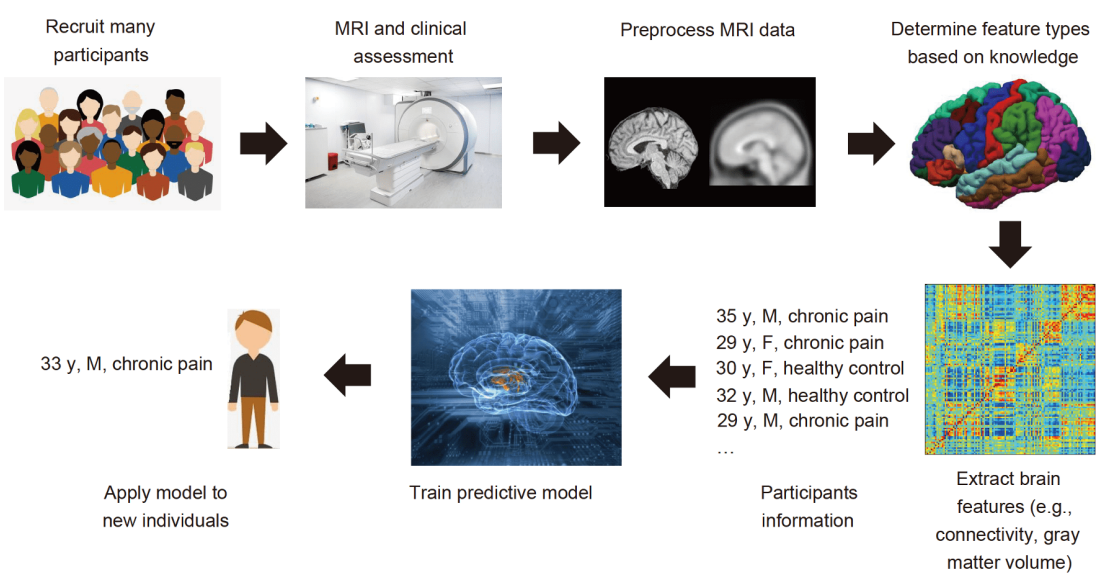

Figure 2 (Color online) Flowchart of machine learning to develop a diagnostic biomarker for chronic pain.

plane in a high-dimensional space to maximize the margin between the boundaries of different classes. Using sMRI gray matter images from patients with chronic pelvic pain and healthy controls, Bagarinao et al. (2014) found that the SVM classifier can discriminate two populations of subjects with an accuracy of 73%, and they identified several brain regions, including the primary somatosensory cortex, pre-SMA, hippocampus, and amygdala, which showed a significant discriminative power. A similar approach was applied to gray matter density of cLBP patients, and an accuracy of 76% for discriminating patients and healthy controls was obtained. The study found that the somatosensory, motor, and prefrontal cortices contributed most in the classification (Ung et al., 2014). Using resting-state functional connectivity and SVM, Tu et al. (2019b) identified abnormal medial prefrontal cortex connectivities, which were able to discriminate cLBP patients from healthy subjects with an accuracy of 91%. Importantly, they validated the performance of the classifier in an independent cohort and obtained an accuracy of 78%, which demonstrated the potential of generating the biomarker and the classifier to new subjects. Other sophisticated machine learning methods, including deep learning approaches, have been applied for identifying biomarkers for fibromyalgia (López-Solà et al., 2017), migraine (Chong et al., 2016), cLBP (Lee et al., 2019), and neuropathic pain (Cheng et al., 2018).

Besides discriminating patients from healthy controls, researchers have attempted to classify different types of chronic pain. For example, two recent studies revealed that gray matter volume patterns could discriminate patients with migraineurs from tension-type headache (Chen et al., 2018) or persistent post-traumatic headache (Schwedt et al., 2017), suggesting that different pathophysiological mechanisms might underlie different types of headaches and the biomarker may be distinct.

Prognostic biomarker and predictive biomarker

The prognostic biomarker has been rarely studied in chronic pain patients. However, the prognostic biomarker can be applied to people who are in acute pain conditions, and it can predict acute pain patients likely to transit from acute to chronic pain. Baliki et al. (2012) found that functional connectivity between the nucleus accumbent and prefrontal cortex predicted the transition from subacute to chronic back pain after 1 year, with an area under the receiver operator curve (a measure to evaluate the accuracy) of 0.81. Another study by Kutch et al. (2017) used functional connectivity to predict the symptom change in urologic chronic pelvic pain patients. They were able to predict short-term (3 months) pain reduction with an accuracy of 73.1% but failed to predict long-term (6 months and 12 months) symptom change.

Patients are unique, and they respond differently to a treatment. Although the treatment can be effective at the group level, some patients may not respond to it. Predictive biomarkers aim to use the baseline brain measures to predict the individual's responses to a certain treatment or intervention after one month or longer, thereby facilitating the development of treatment plans to optimize time, cost, and available resources. Ideally, such a biomarker has the potential to identify patients who have a high chance to benefit from the treatment and those who may not be able to respond. Two recent studies have explored the fMRI predictive biomarker for neuropathic pain relief from ketamine infusion (Bosma et al., 2018; Rogachov et al., 2019). The infusion of ketamine led to the relief of pain in about 50% of chronic neuropathic pain patients. The authors found that the magnitude of temporal summation of pain and the dynamic engagement of the descending pain modulatory circuit predicted the treatment efficacy. In a later study, Liu et al. (2019) found that the baseline functional connectivity between the dorsolateral prefrontal cortex and the SMA was able to predict the effect of 3-month mind-body exercise on pain improvement in knee osteoarthritis patients. An interesting study showed that both 1-month real and sham acupuncture could reduce pain severity in cLBP patients, but different pre-treatment resting-state functional connectivity were predictive for real and sham treatment (Tu et al., 2019c). This phenomenon was also found by another innovative study that used graphical measures to predict the magnitude of placebo responses to treatment for knee osteoarthritis (Tétreault et al., 2016). The right midfrontal gyrus was key brain regions to identify placebo responders. This effect was tested in an independent cohort and had an area under the curve of 0.95, but the biomarker for placebo treatment was not effective for predicting duloxetine treatment. In addition, the placebo response in the treatment of migraine patients was able to be predicted by the DTI white matter features along the fiber pathways of the mPFC-amygdala (Liu et al., 2019).

Guidelines to evaluate neuroimaging-based biomarkers for chronic pain

Whether pain biomarkers should be used for clinical purposes is still under debate (Davis et al., 2017). Defining appropriate guidelines to evaluate pain biomarkers should be cautious. There are many such criteria for a valid and useful biomarker that should be met. Here, we only discuss several important criteria that are necessary to facilitate neuroimaging-based pain biomarkers. First of all, the sensitivity (i.e., hit rate), which is the possibility that a biomarker will yield a positive test result when a pain condition is present, should be carefully evaluated. Second, the specificity, which is the likelihood that a biomarker will respond in the absence of a condition, is very important to reduce false alarms (e.g.,

identify a healthy participant as a chronic pain patient). Third, generalizability, which refers to whether a prediction will be valid when applied to novel test data, is necessary to be evaluated. Last, the interpretability, whether a biomarker is biologically meaningful and supported by plausible mechanisms, is important to link brain responses to behaviors.

In a recent novel investigation by Tu et al. (2020b), the authors designed four studies to identify and evaluate an fMRI based neural biomarker for migraine patients. In the first study, they identified a neural biomarker with abnormal functional connectivity that could classify migraineurs from healthy controls with a sensitivity of 93% and a specificity of 83%. In the second study, they investigated the generalizability of the biomarker by applying it to an independent cohort of subjects (migraineurs and healthy controls) and achieved a sensitivity and specificity of 84%, suggesting that the biomarker could be generalized to new patients. In the third study, they verified the specificity of the biomarker towards other chronic pain disorders (cLBP and fibromyalgia) and demonstrated a sensitivity of 78% and a specificity of 76% for discriminating migraineurs from non-migraineurs. This finding is key to show that the identified biomarker might only respond to migraine patients and captured distinct characteristics of migraine but not respond to other chronic pains. In the fourth study, they observed that the changes in the biomarker showed a significant correlation with the frequency changes in headache due to real acupuncture treatment. Therefore, the biomarker linked disease pattern changes (i.e., headache frequency) to brain changes, and held the ability to evaluate the performance of a treatment for migraine.

Prospects and conclusion

Although promising, identifying chronic pain biomarkers in patients is still challenging, owing to a number of considerations. First, the patient's variability is large. As compared with healthy controls, neuroimaging studies have identified some general abnormalities in patients across different chronic pain conditions, but these findings vary markedly between different individuals. Each patient with chronic pain is marked by a unique contribution of sensory, emotional, cognitive, and motivational components to the experience of pain. Therefore, incorporating patient's variability in the personal characteristics (e.g., emotions, personality), experimental design (including measures affect MRI signals, for example, caffeine assumption), and statistical models (e.g., considering both between-cohort and within-cohort variability) is highly needed to identify clinically useful biomarkers for chronic pain in future studies (Wu et al., 2020). Second, the specificity of identified biomarkers is not justified. Yet, no brain areas or networks have been specifically and exclusively linked to chronic pain. For example, since the comorbidity between chronic pain and mental disorders (such as depression and anxiety) is very high, the identified brain abnormalities may not be necessarily pain-related, but associated with the comorbidity of mental disorders. Future studies with more specific experimental controls are needed to isolate biomarkers with pain specificity. Last but not least, translating the biomarker to clinical applications is far-reaching. Dozens of neuroimaging-based biomarkers for chronic pain have been developed, but their clinical applications have yet been well-explored. How to translate the findings from the laboratory to clinical settings should be carefully carved in the future. This should not be limited to experimental and technical considerations, but also be considered as medical, legal, and ethical issues (Davis et al., 2017).

In summary, the rapid development of neuroimaging techniques and advanced analytical approaches have significantly extended our understandings of the role of the central nervous system in the development and maintenance of chronic pain. Neuroimaging-based diagnostic, prognostic, and predictive biomarkers have been developed for preclinical applications. Future studies can target and modulate these biomarkers to study the causal relationships between brain and chronic pain, moving from neural observations to mechanistic manipulations. Translating findings from laboratories to develop pain evaluation and intervention applications with high clinical utilities is important to bridge basic research and clinical applications.

Compliance and ethics *The author(s) declare that they have no conflict of interest.*

Acknowledgements *This work was supported by the National Natural Science Foundation of China (32071061, 31822025, 31671141, 31800926), and the Scientific Foundation of Institute of Psychology, Chinese Academy of Sciences (E0CX521003).*

References

Abrahamsen, R., Dietz, M., Lodahl, S., Roepstorff, A., Zachariae, R., Østergaard, L., and Svensson, P. (2010). Effect of hypnotic pain modulation on brain activity in patients with temporomandibular disorder pain. Pain 151, 825–833.

Alexander, A.L., Lee, J.E., Lazar, M., and Field, A.S. (2007). Diffusion tensor imaging of the brain. Neurotherapeutics 4, 316–329.

Alshuft, H.M., Condon, L.A., Dineen, R.A., and Auer, D.P. (2016). Cerebral cortical thickness in chronic pain due to knee osteoarthritis: The effect of pain duration and pain sensitization. PLoS ONE 11, e0161687.

Amin, F.M., Hougaard, A., Magon, S., Sprenger, T., Wolfram, F., Rostrup, E., and Ashina, M. (2018). Altered thalamic connectivity during spontaneous attacks of migraine without aura: A resting-state fMRI study. Cephalalgia 38, 1237–1244.

Androulakis, X.M., Krebs, K., Peterlin, B.L., Zhang, T., Maleki, N., Sen, S., Rorden, C., and Herath, P. (2017). Modulation of intrinsic resting-state fMRI networks in women with chronic migraine. Neurology 89, 163–169.

Antal, A., Polania, R., Schmidt-Samoa, C., Dechent, P., and Paulus, W. (2011). Transcranial direct current stimulation over the primary motor cortex during fMRI. NeuroImage 55, 590–596.

Apkarian, V.A., Sosa, Y., Krauss, B.R., Thomas, S.P., Fredrickson, B.E., Levy, R.E., Harden, N.R., and Chialvo, D.R. (2004). Chronic pain patients are impaired on an emotional decision-making task. Pain 108, 129–136.

Arkink, E.B., Schmitz, N., Schoonman, G.G., van Vliet, J.A., Haan, J., van Buchem, M.A., Ferrari, M.D., and Kruit, M.C. (2017). The anterior hypothalamus in cluster headache. Cephalalgia 37, 1039–1050.

Arngrim, N., Hougaard, A., Ahmadi, K., Vestergaard, M.B., Schytz, H.W., Amin, F.M., Larsson, H.B.W., Olesen, J., Hoffmann, M.B., and Ashina, M. (2017). Heterogenous migraine aura symptoms correlate with visual cortex functional magnetic resonance imaging responses. Ann Neurol 82, 925–939.

Arnold, L.M., Lu, Y., Crofford, L.J., Wohlreich, M., Detke, M.J., Iyengar, S., and Goldstein, D.J. (2004). A double-blind, multicenter trial comparing duloxetine with placebo in the treatment of fibromyalgia patients with or without major depressive disorder. Arthritis Rheum 50, 2974–2984.

Aurora, S., Cao, Y., Bowyer, S., and Welch, K.M.A. (1999). The occipital cortex is hyperexcitable in migraine: experimental evidence. Headache 39, 469–476.

Bagarinao, E., Johnson, K.A., Martucci, K.T., Ichesco, E., Farmer, M.A., Labus, J., Ness, T.J., Harris, R., Deutsch, G., Apkarian, V.A., et al. (2014). Preliminary structural MRI based brain classification of chronic pelvic pain: A MAPP network study. Pain 155, 2502–2509.

Baliki, M.N., Baria, A.T., and Apkarian, A.V. (2011). The cortical rhythms of chronic back pain. J Neurosci 31, 13981–13990.

Baliki, M.N., Geha, P.Y., Apkarian, A.V., and Chialvo, D.R. (2008). Beyond feeling: chronic pain hurts the brain, disrupting the default-mode network dynamics. J Neurosci 28, 1398–1403.

Baliki, M.N., Petre, B., Torbey, S., Herrmann, K.M., Huang, L., Schnitzer, T.J., Fields, H.L., and Apkarian, A.V. (2012). Corticostriatal functional connectivity predicts transition to chronic back pain. Nat Neurosci 15, 1117–1119.

Baron, R., Binder, A., and Wasner, G. (2010). Neuropathic pain: Diagnosis, pathophysiological mechanisms, and treatment. Lancet Neurol 9, 807–819.

Barroso, J., Vigotsky, A.D., Branco, P., Reis, A.M., Schnitzer, T.J., Galhardo, V., and Apkarian, A.V. (2020). Brain gray matter abnormalities in osteoarthritis pain: a cross-sectional evaluation. Pain 161, 2167–2178.

Becerra, L., Morris, S., Bazes, S., Gostic, R., Sherman, S., Gostic, J., Pendse, G., Moulton, E., Scrivani, S., Keith, D., et al. (2006). Trigeminal neuropathic pain alters responses in CNS circuits to mechanical (brush) and thermal (cold and heat) stimuli. J Neurosci 26, 10646–10657.

Becerra, L., Schwartzman, R.J., Kiefer, R.T., Rohr, P., Moulton, E.A., Wallin, D., Pendse, G., Morris, S., and Borsook, D. (2009). CNS measures of pain responses pre- and post-anesthetic ketamine in a patient with complex regional pain syndrome. Pain Med 16, 2368–2385.

Berman, B.M., Langevin, H.M., Witt, C.M., and Dubner, R. (2010). Acupuncture for chronic low back pain. N Engl J Med 363, 454–461.

Biswal, B., Zerrin Yetkin, F., Haughton, V.M., and Hyde, J.S. (1995). Functional connectivity in the motor cortex of resting human brain using echo-planar MRI. Magn Reson Med 34, 537–541.

Borsook, D., Edwards, R., Elman, I., Becerra, L., and Levine, J. (2013). Pain and analgesia: the value of salience circuits. Prog Neurobiol 104, 93–105.

Borsook, D., Maleki, N., Becerra, L., and McEwen, B. (2012). Understanding migraine through the lens of maladaptive stress responses: a model disease of allostatic load. Neuron 73, 219–234.

Bosma, R.L., Cheng, J.C., Rogachov, A., Kim, J.A., Hemington, K.S., Osborne, N.R., Venkat Raghavan, L., Bhatia, A., and Davis, K.D. (2018). Brain dynamics and temporal summation of pain predicts neuropathic pain relief from ketamine infusion. Anesthesiology 129, 1015–1024.

Burgmer, M., Gaubitz, M., Konrad, C., Wrenger, M., Hilgart, S., Heuft, G., and Pfleiderer, B. (2009). Decreased gray matter volumes in the cingulo-frontal cortex and the amygdala in patients with fibromyalgia. Psychosom Med 71, 566–573.

Burke, M.J., Joutsa, J., Cohen, A.L., Soussand, L., Cooke, D., Burstein, R., and Fox, M.D. (2020). Mapping migraine to a common brain network. Brain 143, 541–553.

Cagnie, B., Coppieters, I., Denecker, S., Six, J., Danneels, L., and Meeus, M. (2014). Central sensitization in fibromyalgia? A systematic review on structural and functional brain MRI. Semin Arthritis Rheum 44, 68–75.

Cao, J., Orr, S.P., Wilson, G., and Kong, J. (2020). Imagined and actual acupuncture effects on chronic low back pain: a preliminary study. Neural Plast 2020, 1–9.

Cao, J., Tu, Y., Orr, S.P., Lang, C., Park, J., Vangel, M., Chen, L., Gollub, R., and Kong, J. (2018). Analgesic effects evoked by real and imagined acupuncture: a neuroimaging study. Cereb Cortex 29, 3220–3231.

Chappell, A.S., Desaiah, D., Liu-Seifert, H., Zhang, S., Skljarevski, V., Belenkov, Y., and Brown, J.P. (2011). A double-blind, randomized, placebo-controlled study of the efficacy and safety of duloxetine for the treatment of chronic pain due to osteoarthritis of the knee. Pain Pract 11, 33–41.

Chappell, A.S., Ossanna, M.J., Liu-Seifert, H., Iyengar, S., Skljarevski, V., Li, L.C., Bennett, R.M., and Collins, H. (2009). Duloxetine, a centrally acting analgesic, in the treatment of patients with osteoarthritis knee pain: A 13-week, randomized, placebo-controlled trial. Pain 146, 253–260.

Chen, W.T., Chou, K.H., Lee, P.L., Hsiao, F.J., Niddam, D.M., Lai, K.L., Fuh, J.L., Lin, C.P., and Wang, S.J. (2018). Comparison of gray matter volume between migraine and "strict-criteria" tension-type headache. J Headache Pain 19, 4.

Chen, X., Spaeth, R.B., Retzepi, K., Ott, D., and Kong, J. (2014). Acupuncture modulates cortical thickness and functional connectivity in knee osteoarthritis patients. Sci Rep 4, 6482.

Chen, Z., Chen, X., Liu, M., Liu, S., Ma, L., and Yu, S. (2017). Disrupted functional connectivity of periaqueductal gray subregions in episodic migraine. J Headache Pain 18, 36.

Cheng, J.C., Rogachov, A., Hemington, K.S., Kucyi, A., Bosma, R.L., Lindquist, M.A., Inman, R.D., and Davis, K.D. (2018). Multivariate machine learning distinguishes cross-network dynamic functional connectivity patterns in state and trait neuropathic pain. Pain 159, 1764–1776.

Chong, C.D., Dumkrieger, G.M., and Schwedt, T.J. (2017). Structural covariance patterns in migraine: a cross-sectional study exploring the role of the hippocampus. Headache 57, 1522–1531.

Chong, C.D., Gaw, N., Fu, Y., Li, J., Wu, T., and Schwedt, T.J. (2016). Migraine classification using magnetic resonance imaging resting-state functional connectivity data. Cephalalgia 37, 828–844.

Chong, C.D., Schwedt, T.J., and Hougaard, A. (2019). Brain functional connectivity in headache disorders: A narrative review of MRI investigations. J Cereb Blood Flow Metab 39, 650–669.

Coppola, G., Di Renzo, A., Tinelli, E., Di Lorenzo, C., Scapeccia, M., Parisi, V., Serrao, M., Evangelista, M., Ambrosini, A., Colonnese, C., et al. (2018). Resting state connectivity between default mode network and insula encodes acute migraine headache. Cephalalgia 38, 846–854.

Coppola, G., Di Renzo, A., Tinelli, E., Lepre, C., Di Lorenzo, C., Di Lorenzo, G., Scapeccia, M., Parisi, V., Serrao, M., Colonnese, C., et al. (2016). Thalamo-cortical network activity between migraine attacks: Insights from MRI-based microstructural and functional resting-state network correlation analysis. J Headache Pain 17, 100.

Damaraju, E., Allen, E.A., Belger, A., Ford, J.M., McEwen, S., Mathalon, D.H., Mueller, B.A., Pearlson, G.D., Potkin, S.G., Preda, A., et al. (2014). Dynamic functional connectivity analysis reveals transient states of dysconnectivity in schizophrenia. NeuroImage Clin 5, 298–308.

Davis, K.D., Flor, H., Greely, H.T., Iannetti, G.D., Mackey, S., Ploner, M.,

Pustilnik, A., Tracey, I., Treede, R.D., and Wager, T.D. (2017). Brain imaging tests for chronic pain: Medical, legal and ethical issues and recommendations. Nat Rev Neurol 13, 624–638.

DeSouza, D.D., Hodaie, M., and Davis, K.D. (2014). Abnormal trigeminal nerve microstructure and brain white matter in idiopathic trigeminal neuralgia. Pain 155, 37–44.

DeSouza, D.D., Moayedi, M., Chen, D.Q., Davis, K.D., and Hodaie, M. (2013). Sensorimotor and pain modulation brain abnormalities in trigeminal neuralgia: a paroxysmal, sensory-triggered neuropathic pain. PLoS ONE 8, e66340.

Dhond, R.P., Yeh, C., Park, K., Kettner, N., and Napadow, V. (2008). Acupuncture modulates resting state connectivity in default and sensorimotor brain networks. Pain 136, 407–418.

Egorova, N., Gollub, R.L., and Kong, J. (2015). Repeated verum but not placebo acupuncture normalizes connectivity in brain regions dysregulated in chronic pain. NeuroImage Clin 9, 430–435.

Eickhoff, S.B., Laird, A.R., Grefkes, C., Wang, L.E., Zilles, K., and Fox, P. T. (2009). Coordinate-based activation likelihood estimation meta-analysis of neuroimaging data: A random-effects approach based on empirical estimates of spatial uncertainty. Hum Brain Mapp 30, 2907–2926.

Esmaeilpour, Z., Shereen, A.D., Ghobadi-Azbari, P., Datta, A., Woods, A. J., Ironside, M., O'Shea, J., Kirk, U., Bikson, M., and Ekhtiari, H. (2020). Methodology for tDCS integration with fMRI. Hum Brain Mapp 41, 1950–1967.

Fenton, B.W., Palmieri, P.A., Boggio, P., Fanning, J., and Fregni, F. (2009). A preliminary study of transcranial direct current stimulation for the treatment of refractory chronic pelvic pain. Brain Stimul 2, 103–107.

Flodin, P., Martinsen, S., Löfgren, M., Bileviciute-Ljungar, I., Kosek, E., and Fransson, P. (2014). Fibromyalgia is associated with decreased connectivity between pain- and sensorimotor brain areas. Brain Connect 4, 587–594.

Fregni, F., Boggio, P.S., Lima, M.C., Ferreira, M.J.L., Wagner, T., Rigonatti, S.P., Castro, A.W., Souza, D.R., Riberto, M., Freedman, S. D., et al. (2006). A sham-controlled, phase II trial of transcranial direct current stimulation for the treatment of central pain in traumatic spinal cord injury. Pain 122, 197–209.

Fregni, F., Freedman, S., and Pascual-Leone, A. (2007). Recent advances in the treatment of chronic pain with non-invasive brain stimulation techniques. Lancet Neurol 6, 188–191.

Friston, K.J., Holmes, A.P., Worsley, K.J., Poline, J.P., Frith, C.D., and Frackowiak, R.S.J. (1994). Statistical parametric maps in functional imaging: A general linear approach. Hum Brain Mapp 2, 189–210.

Fu, Z., Caprihan, A., Chen, J., Du, Y., Adair, J.C., Sui, J., Rosenberg, G.A., and Calhoun, V.D. (2019). Altered static and dynamic functional network connectivity in Alzheimer's disease and subcortical ischemic vascular disease: shared and specific brain connectivity abnormalities. Hum Brain Mapp 40, 3203–3221.

Fu, Z., Tu, Y., Di, X., Du, Y., Pearlson, G.D., Turner, J.A., Biswal, B.B., Zhang, Z., and Calhoun, V.D. (2018a). Characterizing dynamic amplitude of low-frequency fluctuation and its relationship with dynamic functional connectivity: An application to schizophrenia. NeuroImage 180, 619–631.

Fu, Z., Tu, Y., Di, X., Du, Y., Sui, J., Biswal, B.B., Zhang, Z., de Lacy, N., and Calhoun, V.D. (2018b). Transient increased thalamic-sensory connectivity and decreased whole-brain dynamism in autism. NeuroImage 190, 191–204.

Giesecke, T., Gracely, R.H., Grant, M.A.B., Nachemson, A., Petzke, F., Williams, D.A., and Clauw, D.J. (2004). Evidence of augmented central pain processing in idiopathic chronic low back pain. Arthritis Rheum 50, 613–623.

Goadsby, P.J., Holland, P.R., Martins-Oliveira, M., Hoffmann, J., Schankin, C., and Akerman, S. (2017). Pathophysiology of migraine: a disorder of sensory processing. Physiol Rev 97, 553–622.

Goldstein, D.J., Lu, Y., Detke, M.J., Lee, T.C., and Iyengar, S. (2005). Duloxetine vs. placebo in patients with painful diabetic neuropathy. Pain 116, 109–118.

Gracely, R.H., Petzke, F., Wolf, J.M., and Clauw, D.J. (2002). Functional magnetic resonance imaging evidence of augmented pain processing in fibromyalgia. Arthritis Rheum 46, 1333–1343.

Gustin, S.M., Peck, C.C., Cheney, L.B., Macey, P.M., Murray, G.M., and Henderson, L.A. (2012). Pain and plasticity: Is chronic pain always associated with somatosensory cortex activity and reorganization? J Neurosci 32, 14874–14884.

Gustin, S.M., Peck, C.C., Wilcox, S.L., Nash, P.G., Murray, G.M., and Henderson, L.A. (2011). Different pain, different brain: Thalamic anatomy in neuropathic and non-neuropathic chronic pain syndromes. J Neurosci 31, 5956–5964.

Hart, L.G., Deyo, R.A., and Cherkin, D.C. (1995). Physician office visits for low back pain. Spine 20, 11–19.

Hemington, K.S., Wu, Q., Kucyi, A., Inman, R.D., and Davis, K.D. (2016). Abnormal cross-network functional connectivity in chronic pain and its association with clinical symptoms. Brain Struct Funct 221, 4203–4219.

Henderson, L.A., Peck, C.C., Petersen, E.T., Rae, C.D., Youssef, A.M., Reeves, J.M., Wilcox, S.L., Akhter, R., Murray, G.M., and Gustin, S.M. (2013). Chronic pain: lost inhibition? J Neurosci 33, 7574–7582.

Hiramatsu, T., Nakanishi, K., Yoshimura, S., Yoshino, A., Adachi, N., Okamoto, Y., Yamawaki, S., and Ochi, M. (2014). The dorsolateral prefrontal network is involved in pain perception in knee osteoarthritis patients. Neurosci Lett 581, 109–114.

Hodkinson, D.J., Wilcox, S.L., Veggeberg, R., Noseda, R., Burstein, R., Borsook, D., and Becerra, L. (2016). Increased amplitude of thalamocortical low-frequency oscillations in patients with migraine. J Neurosci 36, 8026–8036.

Hoffmann, J., and May, A. (2018). Diagnosis, pathophysiology, and management of cluster headache. Lancet Neurol 17, 75–83.

Hougaard, A., Amin, F.M., Larsson, H.B.W., Rostrup, E., and Ashina, M. (2017). Increased intrinsic brain connectivity between pons and somatosensory cortex during attacks of migraine with aura. Hum Brain Mapp 38, 2635–2642.

Hu, L., and Iannetti, G.D. (2016). Painful issues in pain prediction. Trends Neurosci 39, 212–220.

Huang, G., Xiao, P., Hung, Y.S., Iannetti, G.D., Zhang, Z.G., and Hu, L. (2013). A novel approach to predict subjective pain perception from single-trial laser-evoked potentials. NeuroImage 81, 283–293.

Hubbard, C.S., Khan, S.A., Keaser, M.L., Mathur, V.A., Goyal, M., and Seminowicz, D.A. (2014). Altered brain structure and function correlate with disease severity and pain catastrophizing in migraine patients. eNeuro 1, ENEURO.0006-14.2014.

Hui, K.K.S., Liu, J., Makris, N., Gollub, R.L., Chen, A.J.W., I. Moore, C., Kennedy, D.N., Rosen, B.R., and Kwong, K.K. (2000). Acupuncture modulates the limbic system and subcortical gray structures of the human brain: Evidence from fMRI studies in normal subjects. Hum Brain Mapp 9, 13–25.

Hutchison, R.M., Womelsdorf, T., Allen, E.A., Bandettini, P.A., Calhoun, V.D., Corbetta, M., Della Penna, S., Duyn, J.H., Glover, G.H., Gonzalez-Castillo, J., et al. (2013). Dynamic functional connectivity: Promise, issues, and interpretations. NeuroImage 80, 360–378.

Ichesco, E., Puiu, T., Hampson, J.P., Kairys, A.E., Clauw, D.J., Harte, S.E., Peltier, S.J., Harris, R.E., and Schmidt-Wilcke, T. (2016). Altered fMRI resting-state connectivity in individuals with fibromyalgia on acute pain stimulation. Eur J Pain 20, 1079–1089.

Jensen, K.B., Kosek, E., Petzke, F., Carville, S., Fransson, P., Marcus, H., Williams, S.C.R., Choy, E., Giesecke, T., Mainguy, Y., et al. (2009). Evidence of dysfunctional pain inhibition in Fibromyalgia reflected in rACC during provoked pain. Pain 144, 95–100.

Jensen, K.B., Srinivasan, P., Spaeth, R., Tan, Y., Kosek, E., Petzke, F., Carville, S., Fransson, P., Marcus, H., Williams, S.C.R., et al. (2013). Overlapping structural and functional brain changes in patients with long-term exposure to fibromyalgia pain. Arthritis Rheum 65, 3293–3303.

Jensen, M.P., Day, M.A., and Miró, J. (2014). Neuromodulatory treatments for chronic pain: Efficacy and mechanisms. Nat Rev Neurol 10, 167–178.

Jones, C.K., Peters, S.C., and Shannon, H.E. (2005). Efficacy of duloxetine, a potent and balanced serotonergic and noradrenergic reuptake inhibitor, in inflammatory and acute pain models in rodents. J Pharmacol Exp Ther 312, 726–732.

Kim, H., Kim, J., Loggia, M.L., Cahalan, C., Garcia, R.G., Vangel, M.G., Wasan, A.D., Edwards, R.R., and Napadow, V. (2015). Fibromyalgia is characterized by altered frontal and cerebellar structural covariance brain networks. NeuroImage Clin 7, 667–677.

Kim, H., Mawla, I., Lee, J., Gerber, J., Walker, K., Kim, J., Ortiz, A., Chan, S.T., Loggia, M.L., Wasan, A.D., et al. (2020a). Reduced tactile acuity in chronic low back pain is linked with structural neuroplasticity in primary somatosensory cortex and is modulated by acupuncture therapy. NeuroImage 217, 116899.

Kim, M., Mawla, I., Albrecht, D.S., Admon, R., Torrado-Carvajal, A., Bergan, C., Protsenko, E., Kumar, P., Edwards, R.R., Saha, A., et al. (2020b). Striatal hypofunction as a neural correlate of mood alterations in chronic pain patients. NeuroImage 211, 116656.

Kong, J., Kaptchuk, T.J., Polich, G., Kirsch, I., Vangel, M., Zyloney, C., Rosen, B., and Gollub, R.L. (2009). An fMRI study on the interaction and dissociation between expectation of pain relief and acupuncture treatment. NeuroImage 47, 1066–1076.

Kong, J., Spaeth, B., Wey, H.Y., Cheetham, A., Cook, A.H., Jensen, K., Tan, Y., Liu, H., Wang, D., Loggia, M.L., et al. (2013). S1 is associated with chronic low back pain: a functional and structural MRI study. Mol Pain 9, 43.

Kregel, J., Meeus, M., Malfliet, A., Dolphens, M., Danneels, L., Nijs, J., and Cagnie, B. (2015). Structural and functional brain abnormalities in chronic low back pain: A systematic review. Semin Arthritis Rheum 45, 229–237.

Kuchinad, A., Schweinhardt, P., Seminowicz, D.A., Wood, P.B., Chizh, B. A., and Bushnell, M.C. (2007). Accelerated brain gray matter loss in fibromyalgia patients: Premature aging of the brain? J Neurosci 27, 4004–4007.

Kucyi, A., and Davis, K.D. (2014). Dynamic functional connectivity of the default mode network tracks daydreaming. NeuroImage 100, 471–480.

Kutch, J.J., Labus, J.S., Harris, R.E., Martucci, K.T., Farmer, M.A., Fenske, S., Fling, C., Ichesco, E., Peltier, S., Petre, B., et al. (2017). Resting-state functional connectivity predicts longitudinal pain symptom change in urologic chronic pelvic pain syndrome. Pain 158, 1069–1082.

Lee, J., Mawla, I., Kim, J., Loggia, M.L., Ortiz, A., Jung, C., Chan, S.T., Gerber, J., Schmithorst, V.J., Edwards, R.R., et al. (2019). Machine learning-based prediction of clinical pain using multimodal neuroimaging and autonomic metrics. Pain 160, 550–560.

Lefaucheur, J.P., Hatem, S., Nineb, A., Menard-Lefaucheur, I., Wendling, S., Keravel, Y., and Nguyen, J.P. (2006). Somatotopic organization of the analgesic effects of motor cortex rTMS in neuropathic pain. Neurology 67, 1998–2004.

Legrain, V., Iannetti, G.D., Plaghki, L., and Mouraux, A. (2011). The pain matrix reloaded. Prog Neurobiol 93, 111–124.

Leung, A., Donohue, M., Xu, R., Lee, R., Lefaucheur, J.P., Khedr, E.M., Saitoh, Y., André-Obadia, N., Rollnik, J., Wallace, M., et al. (2009). rTMS for suppressing neuropathic pain: a meta-analysis. J Pain 10, 1205–1216.

Li, K., Zhang, Y., Ning, Y., Zhang, H., Liu, H., Fu, C., Ren, Y., and Zou, Y. (2015). The effects of acupuncture treatment on the right frontoparietal network in migraine without aura patients. J Headache Pain 16, 518.

Li, Z., Liu, M., Lan, L., Zeng, F., Makris, N., Liang, Y., Guo, T., Wu, F., Gao, Y., Dong, M., et al. (2016). Altered periaqueductal gray resting state functional connectivity in migraine and the modulation effect of treatment. Sci Rep 6, 20298.

Li, Z., Lan, L., Zeng, F., Makris, N., Hwang, J., Guo, T., Wu, F., Gao, Y., Dong, M., Liu, M., et al. (2017a). The altered right frontoparietal network functional connectivity in migraine and the modulation effect of treatment. Cephalalgia 37, 161–176.

Li, Z., Zeng, F., Yin, T., Lan, L., Makris, N., Jorgenson, K., Guo, T., Wu, F., Gao, Y., Dong, M., et al. (2017b). Acupuncture modulates the abnormal brainstem activity in migraine without aura patients. NeuroImage Clin 15, 367–375.

Liu, H.Y., Chou, K.H., and Chen, W.T. (2018). Migraine and the hippocampus. Curr Pain Headache Rep 22, 13.

Liu, J., Chen, L., Tu, Y., Chen, X., Hu, K., Tu, Y., Lin, M., Xie, G., Chen, S., Huang, J., et al. (2019). Different exercise modalities relieve pain syndrome in patients with knee osteoarthritis and modulate the dorsolateral prefrontal cortex: A multiple mode MRI study. Brain Behav Immun 82, 253–263.

Liu, J., Mu, J., Chen, T., Zhang, M., and Tian, J. (2019). White matter tract microstructure of the mPFC-amygdala predicts interindividual differences in placebo response related to treatment in migraine patients. Hum Brain Mapp 40, 284–292.

Loggia, M.L., Berna, C., Kim, J., Cahalan, C.M., Gollub, R.L., Wasan, A. D., Harris, R.E., Edwards, R.R., and Napadow, V. (2014). Disrupted brain circuitry for pain-related reward/punishment in fibromyalgia. Arthritis Rheumatol 66, 203–212.

Loggia, M.L., Kim, J., Gollub, R.L., Vangel, M.G., Kirsch, I., Kong, J., Wasan, A.D., and Napadow, V. (2013). Default mode network connectivity encodes clinical pain: an arterial spin labeling study. Pain 154, 24–33.

López-Solà, M., Pujol, J., Hernández-Ribas, R., Harrison, B.J., Contreras-Rodríguez, O., Soriano-Mas, C., Deus, J., Ortiz, H., Menchón, J.M., Vallejo, J., et al. (2010). Effects of duloxetine treatment on brain response to painful stimulation in major depressive disorder. Neuropsychopharmacology 35, 2305–2317.

López-Solà, M., Woo, C.W., Pujol, J., Deus, J., Harrison, B.J., Monfort, J., and Wager, T.D. (2017). Towards a neurophysiological signature for fibromyalgia. Pain 158, 34–47.

Lötsch, J., and Ultsch, A. (2018). Machine learning in pain research. Pain 159, 623–630.

Maleki, N., Linnman, C., Brawn, J., Burstein, R., Becerra, L., and Borsook, D. (2012). Her versus his migraine: multiple sex differences in brain function and structure. Brain 135, 2546–2559.

Mansour, A.R., Baliki, M.N., Huang, L., Torbey, S., Herrmann, K.M., Schnitzer, T.J., and Apkarian, V.A. (2013). Brain white matter structural properties predict transition to chronic pain. Pain 154, 2160–2168.

Mao, C.P., and Yang, H.J. (2015). Smaller amygdala volumes in patients with chronic low back pain compared with healthy control individuals. J Pain 16, 1366–1376.

Mao, C.P., Zhang, Q.L., Bao, F.X., Liao, X., Yang, X.L., and Zhang, M. (2014). Decreased activation of cingulo-frontal-parietal cognitive/attention network during an attention-demanding task in patients with chronic low back pain. Neuroradiology 56, 903–912.

Mao, J. (2012). Current challenges in translational pain research. Trends Pharmacol Sci 33, 568–573.

Marlow, N.M., Bonilha, H.S., and Short, E.B. (2013). Efficacy of transcranial direct current stimulation and repetitive transcranial magnetic stimulation for treating fibromyalgia syndrome: a systematic review. Pain Pract 13, 131–145.

Martucci, K.T., Borg, N., MacNiven, K.H., Knutson, B., and Mackey, S.C. (2018). Altered prefrontal correlates of monetary anticipation and outcome in chronic pain. Pain 159, 1494–1507.

Marusak, H.A., Calhoun, V.D., Brown, S., Crespo, L.M., Sala-Hamrick, K., Gotlib, I.H., and Thomason, M.E. (2017). Dynamic functional connectivity of neurocognitive networks in children. Hum Brain Mapp 38, 97–108.

May, A., Ashburner, J., Büchel, C., McGonigle, D.J., Friston, K.J., Frackowiak, R.S.J., and Goadsby, P.J. (1999). Correlation between structural and functional changes in brain in an idiopathic headache syndrome. Nat Med 5, 836–838.

May, A., Bahra, A., Büchel, C., Frackowiak, R.S., and Goadsby, P.J. (1998). Hypothalamic activation in cluster headache attacks. Lancet 352, 275–278.

Mehnert, J., and May, A. (2019). Functional and structural alterations in the migraine cerebellum. J Cereb Blood Flow Metab 39, 730–739.

Messina, R., Filippi, M., and Goadsby, P.J. (2018). Recent advances in headache neuroimaging. Curr Opin Neurol 31, 379–385.

Mhalla, A., Baudic, S., de Andrade, D.C., Gautron, M., Perrot, S., Teixeira, M.J., Attal, N., and Bouhassira, D. (2011). Long-term maintenance of the analgesic effects of transcranial magnetic stimulation in fibromyalgia. Pain 152, 1478–1485.

Moayedi, M., Weissman-Fogel, I., Crawley, A.P., Goldberg, M.B., Freeman, B.V., Tenenbaum, H.C., and Davis, K.D. (2011). Contribution of chronic pain and neuroticism to abnormal forebrain gray matter in patients with temporomandibular disorder. NeuroImage 55, 277–286.

Moayedi, M., Weissman-Fogel, I., Salomons, T.V., Crawley, A.P., Goldberg, M.B., Freeman, B.V., Tenenbaum, H.C., and Davis, K.D. (2012). White matter brain and trigeminal nerve abnormalities in temporomandibular disorder. Pain 153, 1467–1477.

Moisset, X., and Bouhassira, D. (2007). Brain imaging of neuropathic pain. NeuroImage 37, S80–S88.

Mori, F., Codecà, C., Kusayanagi, H., Monteleone, F., Buttari, F., Fiore, S., Bernardi, G., Koch, G., and Centonze, D. (2010). Effects of anodal transcranial direct current stimulation on chronic neuropathic pain in patients with multiple sclerosis. J Pain 11, 436–442.

Mulleners, W.M., Chronicle, E.P., Palmer, J.E., Koehler, P.J., and Vredeveld, J.W. (2001). Visual cortex excitability in migraine with and without aura. Headache 41, 565–572.

Napadow, V., Kettner, N., Liu, J., Li, M., Kwong, K.K., Vangel, M., Makris, N., Audette, J., and Hui, K.K.S. (2007). Hypothalamus and amygdala response to acupuncture stimuli in carpal tunnel syndrome. Pain 130, 254–266.

Napadow, V., Kim, J., Clauw, D.J., and Harris, R.E. (2012). Decreased intrinsic brain connectivity is associated with reduced clinical pain in fibromyalgia. Arthritis Rheum 64, 2398–2403.

Napadow, V., LaCount, L., Park, K., As-Sanie, S., Clauw, D.J., and Harris, R.E. (2010). Intrinsic brain connectivity in fibromyalgia is associated with chronic pain intensity. Arthritis Rheum 62, 2545–2555.

Napadow, V., Makris, N., Liu, J., Kettner, N.W., Kwong, K.K., and Hui, K. K.S. (2005). Effects of electroacupuncture versus manual acupuncture on the human brain as measured by fMRI. Hum Brain Mapp 24, 193–205.

Niddam, D.M., Lai, K.L., Fuh, J.L., Chuang, C.Y.N., Chen, W.T., and Wang, S.J. (2016). Reduced functional connectivity between salience and visual networks in migraine with aura. Cephalalgia 36, 53–66.

Niesters, M., Khalili-Mahani, N., Martini, C., Aarts, L., van Gerven, J., van Buchem, M.A., Dahan, A., and Rombouts, S. (2012). Effect of subanesthetic ketamine on intrinsic functional brain connectivity. Anesthesiology 117, 868–877.

Niesters, M., Martini, C., and Dahan, A. (2014). Ketamine for chronic pain: Risks and benefits. Br J Clin Pharmacol 77, 357–367.

O'Connell, N.E., Wand, B.M., Marston, L., Spencer, S., and DeSouza, L.H. (2010). Non-invasive brain stimulation techniques for chronic pain. Cochrane Database Syst Rev 8, CD008208.

Obermann, M., Rodriguez-Raecke, R., Naegel, S., Holle, D., Mueller, D., Yoon, M.S., Theysohn, N., Blex, S., Diener, H.C., and Katsarava, Z. (2013). Gray matter volume reduction reflects chronic pain in trigeminal neuralgia. NeuroImage 74, 352–358.

Parks, E.L., Gehal, P.Y., Balikil, M.N., Katzl, J., Schnitzerl, T.J., and Apkarianl, A.V. (2011). Brain activity for chronic knee osteoarthritis: Dissociating evoked pain from spontaneous pain. Eur J Pain 15, 843. e1–843.e14.

Plow, E.B., Pascual-Leone, A., and Machado, A. (2012). Brain stimulation in the treatment of chronic neuropathic and non-cancerous pain. J Pain 13, 411–424.

Pujol, J., López-Solà, M., Ortiz, H., Vilanova, J.C., Harrison, B.J., Yücel, M., Soriano-Mas, C., Cardoner, N., and Deus, J. (2009). Mapping brain response to pain in fibromyalgia patients using temporal analysis of fMRI. PLoS ONE 4, 0005224.

Robinson, M.E., O'Shea, A.M., Craggs, J.G., Price, D.D., Letzen, J.E., and Staud, R. (2015). Comparison of machine classification algorithms for fibromyalgia: Neuroimages versus self-report. J Pain 16, 472–477.

Rogachov, A., Bhatia, A., Cheng, J.C., Bosma, R.L., Kim, J.A., Osborne, N.R., Hemington, K.S., Venkatraghavan, L., and Davis, K.D. (2019). Plasticity in the dynamic pain connectome associated with ketamine-induced neuropathic pain relief. Pain 160, 1670–1679.

Rogers, R., Wise, R.G., Painter, D.J., Longe, S.E., and Tracey, I. (2004). An investigation to dissociate the analgesic and anesthetic properties of ketamine using functional magnetic resonance imaging. Anesthesiology 100, 292–301.

Rosazza, C., and Minati, L. (2011). Resting-state brain networks: Literature review and clinical applications. Neurol Sci 32, 773–785.

Schulte, L.H., Allers, A., and May, A. (2017). Hypothalamus as a mediator of chronic migraine. Neurology 88, 2011–2016.

Schulte, L.H., and May, A. (2016). The migraine generator revisited: Continuous scanning of the migraine cycle over 30 days and three spontaneous attacks. Brain 139, 1987–1993.

Schwedt, T.J. (2013). Multisensory integration in migraine. Curr Opin Neurol 26, 248–253.

Schwedt, T.J., Chiang, C.C., Chong, C.D., and Dodick, D.W. (2015). Functional MRI of migraine. Lancet Neurol 14, 81–91.

Schwedt, T.J., Chong, C.D., Peplinski, J., Ross, K., and Berisha, V. (2017). Persistent post-traumatic headache vs. migraine: an MRI study demonstrating differences in brain structure. J Headache Pain 18, 10–1186.

Skljarevski, V., Ossanna, M., Liu-Seifert, H., Zhang, Q., Chappell, A., Iyengar, S., Detke, M., and Backonja, M. (2009). A double-blind, randomized trial of duloxetine versus placebo in the management of chronic low back pain. Eur J Neurol 16, 1041–1048.

Skljarevski, V., Zhang, S., Desaiah, D., Alaka, K.J., Palacios, S., Miazgowski, T., and Patrick, K. (2010). Duloxetine versus placebo in patients with chronic low back pain: A 12-week, fixed-dose, randomized, double-blind trial. J Pain 11, 1282–1290.

Stagg, C.J., O'Shea, J., Kincses, Z.T., Woolrich, M., Matthews, P.M., and Johansen-Berg, H. (2009). Modulation of movement-associated cortical activation by transcranial direct current stimulation. Eur J Neurosci 30, 1412–1423.

Stovner, L.J., Nichols, E., Steiner, T.J., Abd-Allah, F., Abdelalim, A., Al-Raddadi, R.M., Ansha, M.G., Barac, A., Bensenor, I.M., Doan, L.P., et al. (2018). Global, regional, and national burden of migraine and tension-type headache, 1990–2016: a systematic analysis for the Global Burden of Disease Study 2016. Lancet Neurol 17, 954–976.

Su, Q., Song, Y., Zhao, R., and Liang, M. (2019). A review on the ongoing quest for a pain signature in the human brain. Brain Sci Adv 5, 274–287.

Symms, M., Jäger, H.R., Schmierer, K., and Yousry, T.A. (2004). A review of structural magnetic resonance neuroimaging. J Neurol Neurosurg Psychiatry 75, 1235–1244.

Tessitore, A., Russo, A., Giordano, A., Conte, F., Corbo, D., De Stefano, M., Cirillo, S., Cirillo, M., Esposito, F., and Tedeschi, G. (2013). Disrupted default mode network connectivity in migraine without aura. J Headache Pain 14, 89.

Tétreault, P., Mansour, A., Vachon-Presseau, E., Schnitzer, T.J., Apkarian, A.V., and Baliki, M.N. (2016). Brain connectivity predicts placebo response across chronic pain clinical trials. PLoS Biol 14, e1002570.

Tu, Y., Fu, Z., Zeng, F., Maleki, N., Lan, L., Li, Z., Park, J., Wilson, G., Gao, Y., Liu, M., et al. (2019a). Abnormal thalamocortical network dynamics in migraine. Neurology 92, e2706–e2716.

Tu, Y., Jung, M., Gollub, R.L., Napadow, V., Gerber, J., Ortiz, A., Lang, C., Mawla, I., Shen, W., Chan, S.T., et al. (2019b). Abnormal medial prefrontal cortex functional connectivity and its association with clinical symptoms in chronic low back pain. Pain 160, 1308–1318.

Tu, Y., Ortiz, A., Gollub, R.L., Cao, J., Gerber, J., Lang, C., Park, J., Wilson, G., Shen, W., Chan, S.T., et al. (2019c). Multivariate resting-state functional connectivity predicts responses to real and sham acupuncture treatment in chronic low back pain. NeuroImage Clin 23, 101885.

Tu, Y., Fu, Z., Mao, C., Falahpour, M., Gollub, R.L., Park, J., Wilson, G., Napadow, V., Gerber, J., Chan, S.T., et al. (2020a). Distinct thalamocortical network dynamics are associated with the

pathophysiology of chronic low back pain. Nat Commun 11, 3948.
Tu, Y., Zeng, F., Lan, L., Li, Z., Maleki, N., Liu, B., Chen, J., Wang, C., Park, J., Lang, C., et al. (2020b). An fMRI-based neural marker for migraine without aura. Neurology 94, e741–e751.
Tzabazis, A., Aparici, C.M., Rowbotham, M.C., Schneider, M.B., Etkin, A., and Yeomans, D.C. (2013). Shaped magnetic field pulses by multi-coil repetitive transcranial magnetic stimulation (rTMS) differentially modulate anterior cingulate cortex responses and pain in volunteers and fibromyalgia patients. Mol Pain 9, 33.
Ung, H., Brown, J.E., Johnson, K.A., Younger, J., Hush, J., and Mackey, S. (2014). Multivariate classification of structural MRI data detects chronic low back pain. Cereb Cortex 24, 1037–1044.
van der Miesen, M.M., Lindquist, M.A., and Wager, T.D. (2019). Neuroimaging-based biomarkers for pain. Pain Rep 4, e751.
Venkatakrishnan, A., and Sandrini, M. (2012). Combining transcranial direct current stimulation and neuroimaging: Novel insights in understanding neuroplasticity. J Neurophysiol 107, 1–4.
Vickers, A.J., Cronin, A.M., Maschino, A.C., Lewith, G., MacPherson, H., Victor, N., Foster, N.E., Sherman, K.J., Witt, C.M., and Linde, K. (2012). Acupuncture for chronic pain: Individual patient data meta-analysis. Arch Intern Med 172, 1444–1453.
Vickers, A.J., Vertosick, E.A., Lewith, G., MacPherson, H., Foster, N.E., Sherman, K.J., Irnich, D., Witt, C.M., and Linde, K. (2018). Acupuncture for chronic pain: update of an individual patient data meta-analysis. J Pain 19, 455–474.
von Deneen, K.M., Zhao, L., and Liu, J. (2019). Individual differences of maladaptive brain changes in migraine and their relationship with differential effectiveness of treatments. Brain Sci Adv 5, 239–255.
Vos, T., Flaxman, A.D., Naghavi, M., Lozano, R., Michaud, C., Ezzati, M., Shibuya, K., Salomon, J.A., Abdalla, S., Aboyans, V., et al. (2012). Years lived with disability (YLDs) for 1160 sequelae of 289 diseases and injuries 1990–2010: a systematic analysis for the Global Burden of Disease Study 2010. Lancet 380, 2163–2196.
Wager, T.D., Atlas, L.Y., Lindquist, M.A., Roy, M., Woo, C.W., and Kross, E. (2013). An fMRI-based neurologic signature of physical pain. N Engl J Med 368, 1388–1397.
Weissman-Fogel, I., Moayedi, M., Tenenbaum, H.C., Goldberg, M.B., Freeman, B.V., and Davis, K.D. (2011). Abnormal cortical activity in patients with temporomandibular disorder evoked by cognitive and emotional tasks. Pain 152, 384–396.
Woo, C.W., Chang, L.J., Lindquist, M.A., and Wager, T.D. (2017). Building better biomarkers: Brain models in translational neuroimaging. Nat Neurosci 20, 365–377.
Wu, A., Dong, W., Liu, S., Cheung, J.P.Y., Kwan, K.Y.H., Zeng, X., Zhang, K., Sun, Z., Wang, X., Cheung, K.M.C., et al. (2019). The prevalence and years lived with disability caused by low back pain in China, 1990 to 2016. Pain 160, 237–245.
Wu, D., Li, X., and Jiang, T. (2020). Reconstruction of behavior-relevant individual brain activity: an individualized fMRI study. Sci China Life Sci 63, 410–418.
Xue, T., Yuan, K., Zhao, L., Yu, D., Zhao, L., Dong, T., Cheng, P., von Deneen, K.M., Qin, W., and Tian, J. (2012). Intrinsic brain network abnormalities in migraines without aura revealed in resting-state fMRI. PLoS ONE 7, e52927.
Yarkoni, T., Poldrack, R.A., Nichols, T.E., Van Essen, D.C., and Wager, T. D. (2011). Large-scale automated synthesis of human functional neuroimaging data. Nat Methods 8, 665–670.
Yu, S., Li, W., Shen, W., Edwards, R.R., Gollub, R.L., Wilson, G., Park, J., Ortiz, A., Cao, J., Gerber, J., et al. (2020a). Impaired mesocorticolimbic connectivity underlies increased pain sensitivity in chronic low back pain. NeuroImage 218, 116969.
Yu, S., Ortiz, A., Gollub, R.L., Wilson, G., Gerber, J., Park, J., Huang, Y., Shen, W., Chan, S.T., Wasan, A.D., et al. (2020b). Acupuncture treatment modulates the connectivity of key regions of the descending pain modulation and reward systems in patients with chronic low back pain. J Clin Med 9, 1719.
Zang, Y.F., He, Y., Zhu, C.Z., Cao, Q.J., Sui, M.Q., Liang, M., Tian, L.X., Jiang, T.Z., and Wang, Y.F. (2007). Altered baseline brain activity in children with ADHD revealed by resting-state functional MRI. Brain Dev 29, 83–91.
Zhang, J., Su, J., Wang, M., Zhao, Y., Zhang, Q.T., Yao, Q., Lu, H., Zhang, H., Li, G.F., Wu, Y.L., et al. (2017). The sensorimotor network dysfunction in migraineurs without aura: a resting-state fMRI study. J Neurol 264, 654–663.
Zhang, B., Jung, M., Tu, Y., Gollub, R., Lang, C., Ortiz, A., Park, J., Wilson, G., Gerber, J., Mawla, I., et al. (2019a). Identifying brain regions associated with the neuropathology of chronic low back pain: a resting-state amplitude of low-frequency fluctuation study. Br J Anaesth 123, e303–e311.
Zhang, L., Zhou, L., Ren, Q., Mokhtari, T., Wan, L., Zhou, X., and Hu, L. (2019b). Evaluating cortical alterations in patients with chronic back pain using neuroimaging techniques: recent advances and perspectives. Front Psychol 10, 2527.
Zhao, L., Chen, J., Li, Y., Sun, X., Chang, X., Zheng, H., Gong, B., Huang, Y., Yang, M., Wu, X., et al. (2017). The long-term effect of acupuncture for migraine prophylaxis. JAMA Intern Med 177, 508.
Zou, Q.H., Zhu, C.Z., Yang, Y., Zuo, X.N., Long, X.Y., Cao, Q.J., Wang, Y. F., and Zang, Y.F. (2008). An improved approach to detection of amplitude of low-frequency fluctuation (ALFF) for resting-state fMRI: Fractional ALFF. J Neurosci Methods 172, 137–141.

SUPPORTING INFORMATION

The supporting information is available online at https://doi.org/10.1007/s11427-020-1822-4. The supporting materials are published as submitted, without typesetting or editing. The responsibility for scientific accuracy and content remains entirely with the authors.